

CHAPTER 1

INTRODUCTION

Histopathology- Definition it is a branch of pathology which deals with the study of disease in a tissue section.

The tissue undergoes a series of steps before it reaches the examiners desk to be thoroughly examined microscopically to arrive at a particular diagnosis.

To achieve this it is important that the tissue must be prepared in such a manner that it is sufficiently thick or thin to be examined microscopically and all the structures in a tissue may be differentiated.

The objective of the subsequent discussions will be to acquaint the staff with their responsibility; the basic details of tissue handling, processing and staining.

The term **histochemistry** means study of chemical nature of the tissue components by histological methods.

The cell is the single structural unit of all tissues. The study of cell is called cytology.

A tissue is a group of cells specialized and differentiated to perform a specialized function. Collection of different type of cells forms an organ.

Type of material obtained in laboratory

The human tissue comes from the surgery and the autopsy room from surgery two types of tissue are obtained.

1. As biopsy- A small piece of lesions or tumor which is sent for diagnosis before final removal of the lesion or the tumor (Incisional biopsy).
2. If the whole of the tumor or lesion is sent for examination and diagnosis by the pathologist, it is called excisional biopsy.
3. Tissues from the autopsy are sent for the study of disease and its course, for the advancement of medicine.

Types of Histological preparation

The histological specimen can be prepared as

1. Whole mount
 2. Sections
 3. Smears.
1. Whole mounts- These are preparation entire animal eg. fungus, parasite. These preparations should be no more than 0.2-0.5 mm in thickness.
 2. Sections- The majority of the preparations in histology are sections. The tissue is cut in about 3-5 mm thick pieces processed and 5 microns thick sections are cut on a microtome. These are then stained and permanently mounted.

Microtomes are special instruments which have automatic mechanism for cutting very thin sections. To cut the sections on the microtome; the tissue must be made hard enough to not get crushed. There are 2 methods of hardening the tissues. One is by freezing them and the other is by embedding them in a hard material such as paraffin wax or gelatin.

3. Smears- Smears are made from blood, bone marrow or any fluid such as pleural or ascitic fluid. These are immediately fixed in alcohol to preserve the cellular structures are then stained. Smears are also made by crushing soft tissue between two slides or an impression smear is made by pressing a clean slide in contact with the moist surface of a tissue. By doing this, the cells are imprinted on the slide and these may be stained for cytological examination.

PHOENIX PARAMEDICAL COLLEGE PULWAMA KASHMIR

Responsibility of a technician

The technician is responsible for

1. Specimen preservation.
2. Specimen labeling, logging and identification.
3. Preparation of the specimen to facilitate their gross and microscopy.
4. Record keeping.

To obtain these aims the following point need consideration.

1. As soon as the specimen is received in the laboratory, check if the specimen is properly labeled with the name, age, Hospital Registration No. and the nature of tissue to be examined and the requisition form is also duly filled.
2. Also check if the specimen is in proper fixative. Fixative should be fifteen to twenty times the volume of the specimen add fixative if not present in sufficient amount.
3. Check if the financial matters have been taken care off.
4. Make the entries in biopsy register and give the specimen a pathology number called the accession number. Note this number carefully on the requisition form as well as the container. This number will accompany the specimen every where.
5. If the specimen is large inform the pathologist who will make cut in the specimen so that proper fixation is done. Container should be appropriate to hold the specimen without distorting it.

6. Blocks of tissues taken for processing should be left in 10% formalin at 60°C till processing. These would be fixed in 2 hours.
7. Slides should be released for recording after consultation with the pathologist.
8. Specimens should be kept in their marked container and discarded after checking with pathologist.
9. Block must be stored at their proper number the same day. Note the blocks have to be kept preserved for life long. Slides should be stored in their proper number after 3 days. It gives time for the slides to be properly dried.

PHOENIX PARAMEDICAL COLLEGE PULWANA KASHMIR

CHAPTER -2

FIXATION

Definition It is a complex series of chemical events which brings about changes in the various chemical constituents of cell like hardening, however the cell morphology and structural detail is preserved.

Unless a tissue is fixed soon after the removal from the body it will undergo degenerative changes due to autolysis and putrefaction so that the morphology of the individual cell will be lost.

Mode of teaching - Overhead projector and practical demonstration.

Principle of fixation- The fixative brings about crosslinking of proteins which produces denaturation or coagulation of proteins so that the semifluid state is converted into semisolid state; so that it maintains everything in vivo in relation to each other. Thus semisolid state facilitate easy manipulation of tissue.

Aims and Effects of fixation

If a fresh tissue is kept as such at room temperature it will become liquefied with a foul odour mainly due to action of bacteria i.e. putrefaction and autolysis so the first and foremost aim of fixation is

1. To preserve the tissue in as life like manner as possible.
2. To prevent postmortem changes like autolysis and putrefaction.

Autolysis is the lysis or dissolution of cells by enzymatic action probably as a result of rupture of lysosomes.

Putrefaction The breakdown of tissue by bacterial action often with

formation of gas.

3. Preservation of chemical compounds and microanatomic constituents so that further histochemistry is possible.
4. *Hardening* : the hardening effect of fixatives allows easy manipulation of soft tissue like brain, intestines etc.
5. *Solidification*: Converts the normal semifluid consistency of cells (gel) to an irreversible semisolid consistency (solid).
6. *Optical differentiation* - it alters to varying degrees the refractive indices of the various components of cells and tissues so that unstained components are more easily visualized than when unfixed.
7. *Effects of staining* - certain fixatives like formaldehyde intensifies the staining character of tissue especially with haematoxylin.

Properties of fixatives

1. Coagulation and precipitation as described above.
2. Penetration Fixation is done by immersing the tissue in fluid containing the fixative. Faster a fixative can penetrate the tissue better it is penetration power depends upon the molecular weight e.g. formalin fixes faster than osimic acid.
3. Solubility of fixatives - All fixatives should be soluble in a suitable solvent, preferably in water so that adequate concentrations can be prepared.
4. Concentration - It is important that the concentration of fixative is isotonic or hypotonic

5. Reaction - Most fixatives are acidic. It may help in fixation but can affect staining so has to be neutralized e.g. formalin is neutralized by adding of calcium carbonate.

Amount of fixative

The fixative should be at least 15-20 times the bulk of tissue. For museum specimens the volume of fixative is > 50 times.

Note : If the specimen is large then see that the sections are made to make slices which have a thickness of 1.5 cm so that fixative can penetrate the tissue easily

Reagents employed as fixatives (simple fixatives)

- I. **Formaldehyde** - Formaldehyde is a gas but is soluble in water to the extent of 37-40% w/v. This solution of formaldehyde in water is called formalin or full strength formalin. Formalin is one of the commonly used fixative in all laboratories since it is cheap penetrates rapidly and does not over harden the tissues.
- ☐ It preserves the proteins by forming crosslinkage with them and the tissue component.
 - ☐ It denatures the proteins.
 - ☐ Glycogen is partially preserved hence formalin is not a fixative choice for carbohydrates.
 - ☐ Some enzymes can be demonstrated in formalin fixed tissues.
 - ☐ It neither preserves nor destroys fat. Complex lipids are fixed but has

no effect on neutral fat. After formalin fixation fat may be demonstrated in frozen section. Pure formalin is not a satisfactory fixative as it overhardens the tissue. A 10% dilution in water (tap or distilled) is satisfactory.

Since it oxidizes to formic acid if kept standing for long period so it should be neutralized by phosphates or calcium carbonate otherwise it tends to form artifact; a brown pigment in tissues. To remove this pigment picric alcohol or saturated alcoholic sodium hydroxide may be used. Concentrated formalin should never be neutralized as there is a great danger of explosion.

The commercial formalin becomes cloudy on standing especially when stored in a cool place due to formation of precipitate of paraformaldehyde which can be filtered.

Formalin on prolonged exposure can cause either dermatitis its vapour may damage the nasal mucosa and cause sinusitis.

Time required for fixation.

At room temperature	-	12 hours
For small biopsies	-	4-6 hours
At 65°C fixation occurs in	-	2 hours

II. Alcohol (Ethyl Alcohol)

Absolute alcohol alone has very little place in routine fixation for histopathology.

- ☐ It acts as a reducing agents, become oxidized to acetaldehyde and then to acetic acid.

- ☐ It is slow to penetrate, hardens and shrinks the tissue.
- ☐ Alcohol penetrates rapidly in presence of other fixative hence in combination e.g. Carnoy's fixative is used to increase the speed of tissue processing.
- ☐ Ethanol preserves some proteins in relatively undenatured state so that it can be used for immunofluorescence or some histochemical methods to detect certain enzymes.
- ☐ It is a fat solvent hence it dissolves fats and lipids
- ☐ Methyl alcohol is used for fixing blood and bone marrow smears.

III. Acetone : Cold acetone is sometimes used as a fixative for the histochemical demonstration of some tissue enzymes like phosphatases and lipases.

Its mode of action as fixative is similar to that of alcohol

IV. Mercuric Chloride (HgCl₂)

Mercuric chloride is a very good salt employed in fixing but is rarely used alone because it causes shrinkage of the tissue.

- ☐ It brings about precipitation of the proteins which are required to be removed before staining by using potassium iodide in which they are soluble.
- ☐ The size (thickness) of the tissue to be fixed in mercuric chloride is important, since if the tissue is more than 4 mm, then it hardens the tissue at the periphery whereas the centre remains soft & under fixed.

- ☐ It penetrates rapidly without destroying lipids.
- ☐ It neither fixes nor destroys carbohydrates. Treatment of the tissue with mercuric chloride brings out more brilliant staining with most of the dyes.
- ☐ Tissues fixed with mercuric chloride containing fixatives contain black precipitates of mercury which are removed by treating with 0.5% iodide solution in 70% ethanol for 5-10 minutes, sections are rinsed in water, decolourized for 5 minutes in 5% sodium thiosulphate and washed in running water.

V. Picric acid - It produces marked cells shrinkage hence it is not used alone.

It has to be stored in a damp place because of its explosive nature it is preferably stored under a layer of water.

Advantage It penetrates well and fixes rapidly.

It precipitates proteins and combines with them to form picrates some of the picrates are water-soluble so must be treated with alcohol before further processing where the tissue comes into contact with water.

Note : All the tissues fixed in picric acid containing fixatives should be thoroughly washed to remove the yellow discolouration to ensure proper staining of tissue sections.

If the fixative is not removed by washing thoroughly with time even the embedded tissue loses its staining quality.

VI. Potassium dichromate

It fixes the cytoplasm without precipitation. Valuable in mixtures for the fixation of lipids especially phospholipids. Used for fixing phosphatides and mitochondria.

Note - Thorough washing of the tissue fixed in dichromate is required to avoid forming an oxide in alcohol which cannot be removed later.

VII. Osmium tetroxide - It is a strong oxidizing agent and brings about fixation by forming cross links with proteins.

- ☐ It gives excellent preservation of details of a cell, therefore exclusively used for electron microscopy.
- ☐ It fixes fat e.g. myelin.
- ☐ It also demonstrates fat when 0.5-2% aqueous solution is used it gives a black colour to fat.

VIII. Acetic acid - It causes the cells to swell hence can never be used alone but should be used with fixatives causing cell shrinkage

IX. Glutaraldehyde - It is used alone or in combination with osmium tetroxide for electron microscopy.

Compound fixatives - Some fixatives are made by combining one or more fixative so that the disadvantage of one are reduced by use of another fixative.

All these compound fixative have their own advantages and disadvantages. They should be used judiciously.

Choice of fixative - The choice of fixative depends on the treatment a tissue is going to receive after fixation e.g. what is the chemical structure that needs to be stained ? If fat is to be demonstrated the formalin fixed tissue is better. For demonstration of glycogen formalin should never be used instead alcohol should be the choice of fixative

Preparation of the specimen for fixation

1. For achieving good fixation it is important that the fixative penetrates the tissue well hence the tissue section should be $\geq 4\text{mm}$ thick, so that fixation fluid penetrates from the periphery to the centre of the tissue. For fixation of large organs perfusion method is used i.e. fixative is injected through the blood vessels into the organ. For hollow viscera fixative is injected into the cavity e.g. urinary bladder, eyeball etc.
2. Ratio of volume of fixative to the specimen should be 1:20.
3. Time necessary for fixation is important routinely 10% aqueous formalin at room temperature takes 12 hours to fix the tissue. At higher temperature i.e. $60-65^{\circ}\text{C}$ the time for fixation is reduced to 2 hours.

Fixatives are divided into three main groups

- A. Microanatomical fixatives - such fixatives preserves the anatomy of the tissue.

- B. Cytological fixatives - such fixation are used to preserve intracellular structures or inclusion.
- C. Histochemical fixatives : Fixative used to preserve the chemical nature of the tissue for it to be demonstrated further. Freeze drying technique is best suited for this purpose.

Microanatomical fixatives

1. 10% (v/v) formalin in 0.9% sodium chloride (normal saline). This has been the routine fixative of choice for many years, but this has now been replaced by buffered formal or by formal calcium acetate
 2. Buffered formalin
 - (a) Formalin 10ml
 - (b) Acid sodium phosphate - 0.4 gm
(monohydrate)
 - (c) Anhydrous disodium - 0.65 gm
phosphate
 - (d) Water to 100 ml

-Best overall fixative
 3. Formal calcium (Lillie : 1965)
 - (a) Formalin : 10 ml
 - (b) Calcium acetate 2.0 gm
 - (c) Water to 100 ml
- ☐ Specific features
- They have a near neutral pH
 - Formalin pigment (acid formaldehyde haematin) is not formed.

4. Buffered formal sucrose (Holt and Hicks, 1961)

- (a) Formalin : 10ml
- (b) Sucrose : 7.5 gm
- (c) M/15 phosphate to 100 ml
buffer (pH 7.4)

☐ Specific features

- This is an excellent fixative for the preservation of fine structure phospholipids and some enzymes.
- It is recommended for combined cytochemistry and electron microscopic studies.
- It should be used cold (4°C) on fresh tissue.

5. Alcoholic formalin

- | | |
|----------------|-------|
| Formalin | 10 ml |
| 70-95% alcohol | 90 ml |

6. Acetic alcoholic formalin

- | | |
|---------------------|---------|
| Formalin | 5.0ml |
| Glacial acetic acid | 5.0 ml |
| Alcohol 70% | 90.0 ml |

7. Formalin ammonium bromide

- | | |
|-----------------|---------|
| Formalin | 15.0 ml |
| Distilled water | 85.0 ml |
| Ammonia bromide | 2.0 gm |

- ☐ Specific features : Preservation of neurological tissues especially when gold and silver impregnation is employed

8. Heidenhain Susa

- (a) Mercuric chloride 4.5gm
- (b) Sodium chloride 0.5 gm
- (c) Trichloroacetic acid 2.0 gm
- (d) Acetic acid 4.0 ml
- (e) Distilled water to 100 ml

☐ Specific features

- Excellent fixative for routine biopsy work
- Allows brilliant staining with good cytological detail
- Gives rapid and even penetration with minimum shrinkage
- Tissue left in it for over 24 hours becomes bleached and excessively hardened.
- Tissue should be treated with iodine to remove mercury pigment

9. Zenker's fluid

- (a) Mercuric chloride 5gm
- (b) Potassium dichromate 2.5 gm
- (c) Sodium sulphate 1.0 gm
- (d) Distilled water to 100 ml
- (e) Add immediately before use : Glacial acetic acid : 5 ml

☐ Specific features

- Good routine fixative
- Give fairly rapid and even penetration
- It is not stable after the addition of acetic acid hence acetic acid (or formalin) should be added just before use

- Washing of tissue in running water is necessary to remove excess dichromate

10. Zenker formal (Helly's fluid)

- (a) Mercuric chloride - 5 gm
- (b) Potassium dichromate 2.5 gm
- (c) Sodium sulphate 1.0 gm
- (d) Distilled water to 100 ml
- (e) Add formalin immediately before use 5 ml

☐ Specific features

- It is excellent microanatomical fixative
- Excellent fixative for bone marrow spleen and blood containing organs
- As with Zenker's fluid it is necessary to remove excess dichromate and mercuric pigment

11. B5 stock solution

- Mercuric chloride 12 gm
- Sodium acetate 2.5gm
- Distilled water 200ml

B5 Working solution

- B5 stock solution 20ml
- Formalin (40% w/v formaldehyde) 2 ml

☐ Specific Features

- B5 is widely advocated for fixation of lymphnode biopsies both to improve the cytological details and to enhance immunoreactivity with

antiimmunoglobulin antiserum used in phenotyping of B cell neoplasm.

Procedure

Prepare working solution just before use

Fix small pieces of tissue (7x7x2.5mm) for 1-6 hours at room temperature

Process routinely to paraffin.

12. Bouin's fluid

- | | | |
|-----|-------------------------------|------|
| (a) | Saturated aqueous picric acid | 75ml |
| (b) | Formalin | 25ml |
| (c) | Glacial acetic acid | 5 ml |

☐ Specific features

- Penetrates rapidly and evenly and causes little shrinkage
- Excellent fixative for testicular and intestinal biopsies because it gives very good nuclear details, in testes is used for oligospermia and infertility studies
- Good fixative for glycogen
- It is necessary to remove excess picric acid by alcohol treatment

13. Gender's fluid - better fixative for glycogen.

- | | | |
|-----|---|------|
| (a) | Saturated picric acid in 95% v/v/ alcohol | 80ml |
| (b) | Formalin | 15ml |
| (c) | Glacial acetic acid | 5ml |

Cytological fixatives

Subdivided into

- (A) Nuclear fixatives
- (B) Cytoplasmic fixatives

A. **Nuclear fixatives** : As the name suggests it gives good nuclear fixation. This group includes

1. Carnoy's fluid.

- (a) Absolute alcohol 60ml
- (b) Chloroform 30ml
- (c) Glacial acetic acid 10 ml

□ Specific features

- It penetrates very rapidly and gives excellent nuclear fixation.
- Good fixative for carbohydrates.
- Nissl substance and glycogen are preserved.
- It causes considerable shrinkage.
- It dissolves most of the cytoplasmic elements. Fixation is usually complete in 1-2 hours.

For small pieces 2-3 mm thick only 15 minutes in needed for fixation.

2. Clarke's fluid

- (a) Absolute alcohol 75 ml
- (b) Glacial acetic acid 25 ml.

☐ Specific features

- Rapid, good nuclear fixation and good preservation of cytoplasmic elements.
- It is excellent for smear or cover slip preparation of cell cultures or chromosomal analysis.

3. New Comer's fluid.

- | | | |
|-----|-----------------|--------|
| (a) | Isopropanolol | 60 ml |
| (b) | Propionic acid | 40ml |
| (c) | Petroleum ether | 10 ml. |
| (d) | Acetone | 10 ml. |
| (e) | Dioxane | 10 ml. |

☐ Specific features

- Designed for fixation of chromosomes
- It fixes and preserves mucopolysaccharides. Fixation is complete in 12-18 hours.

(b) Cytoplasmic Fixatives

(1) Champy's fluid

- | | | |
|-----|----------------------------|-------|
| (a) | 3g/dl Potassium dichromate | 7ml. |
| (b) | 1% (V/V) chromic acid | 7 ml. |
| (c) | 2gm/dl osmium tetroxide | 4 ml. |

☐ Specific features

- This fixative cannot be kept hence prepared fresh.
- It preserves the mitochondrial fat and lipids.

- Penetration is poor and uneven.
- Tissue must be washed overnight after fixation.

(2) Formal saline and formal Calcium

Fixation in formal saline followed by postchromatization gives good cytoplasmic fixation.

Histochemical fixatives

For a most of the histo chemical methods. It is best to use cryostat. Sections are rapidly frozen or freeze dried. Usually such sections are used unfixed but if delay is inevitable then vapour fixatives are used.

Vapour fixatives

1. Formaldehyde- Vapour is obtained by heating paraformaldehyde at temperature between 50° and 80°C. Blocks of tissue require 3-5 hours whereas section require ½- 1 hours.
2. Acetaldehyde- Vapour at 80°C for 1-4 hours.
3. Glutaraldehyde- 50% aqueous solution at 80°C for 2 min to 4 hours.
4. Acrolein /chromyl chloride- used at 37°C for 1-2 hours

Other more commonly used fixatives are (1) formal saline (2) Cold acetone Immersing in acetone at 0-4°C is widely used for fixation of tissues intended to study enzymes esp. phosphates. (3) Absolute alcohol for 24 hours.

Secondary fixation - Following fixation in formalin it is sometimes useful to submit the tissue to second fixative eg. mercuric chloride for 4 hours. It provided firmer texture to the tissues and gives brilliance to the staining.

Post chromation- It is the treatment and tissues with 3% potassium dichromate following normal fixation. Post chromatization is carried out either before processing, when tissue is for left for 6-8 days in dichromate solution or after processing when the sections are immersed in dichromate solution, In for 12-24 hours, in both the states washing well in running water is essential. This technique is used a mordant to tissues.

Washing out- After the use of certain fixative it is urgent that the tissues be thoroughly washed in running water to remove the fixative entirely. Washing should be carried out ideally for 24 hours.

Tissues treated with potassium dichromate, osmium tetroxide and picric acid particularly need to be washed thoroughly with water prior to treatment with alcohol (for dehydration).

Tissue	Fixative of choice	Time for fixative
Routine	Formalin	10-12 hours.
GIT biopsies	buffered formaldehyde	4-6 hours
Testicular biopsy	Bouin's fixative	4-6 Hours.
Liver Biopsy	Buffered formaldehyde	4-12 hours.
Bone marrow biopsy	Bouin's fixative in running	2½ hours followed by washing in running water overnight
Spleen and blood filled cavities	Zenker's fluid	1-6 hours
Lymph node	B5	12-18 hours
Mitochondria, phosphatides and Nissl substance	Carnoy's fluid	1-2 hours
Chromosome / cell culture	Clarke's fluid	1-2 hours

CHAPTER 3

DECALCIFICATION

Specific Objective - The aim of the study is to ensure staining of hard bony lesions so that the study of pathological lesions is possible.

Mode of teaching - Overhead projector and practical demonstration.

Definition Decalcification is a process of complete removal of calcium salt from the tissues like bone and teeth and other calcified tissues following fixation.

Decalcification is done to assure that the specimen is soft enough to allow cutting with the microtome knife. Unless the tissues are completely decalcified the sections will be torn and ragged and may damage the cutting edge of microtome knife.

The steps of decalcification

1. To ensure adequate fixation and complete removal of the calcium it is important that the slices are 4-5 mm thick. Calcified tissue needs 2-3 hours only, for complete decalcification to be achieved so it is necessary to check the decalcification after 2-3 hours.
2. Fixative of choice for bone or bone marrow is Zenker formal or Bouin's fluid. Unfixed tissue tends to be damaged 4 times greater during decalcification than a properly fixed tissue.

Decalcification

Decalcification is effected by one of the following methods.

- (a) Dissolution of calcium by a dilute mineral acid.

- (b) Removal of calcium by use of dilute mineral and along with ion exchange resin to keep the decalcifying fluid free of calcium.
- (c) Using Chelating agents EDTA.
- (d) Electrolytic removal of calcium ions from tissue by use of electric current.

The Criteria of a good decalcifying agents area.

1. Complete removal of calcium.
2. Absence of damage to tissue cells or fibres.
3. Subsequent staining not altered.
4. Short time required for decalcification.

Removal of calcium by mineral acids - Acid decalcifies subdivided into- Strong acid, weak acid.

Strong acid - eg. Nitric and hydrochloric acid.

Nitric acid- 5-10% aqueous solution used.

They decalcify very rapidly but if used for longer than 24-48 hrs. cause deterioration of stainability specially of the nucleus

Hydrochloric acid - 5-10% aqueous solution decalcification slower than nitric acid but still rapid. Fairly good nuclear staining.

Weak acid e.g. formic, acetic and picric acid of these formic acids is extensively used as acid decalcifier. 5-10% aqueous solution or with additives like formalin or buffer are used.

Formic acid

1. Brings out fairly rapid decalcification.
2. Nuclear staining in better.
3. But requires neutralization and thorough washing prior to dehydration.

Aqueous nitric acid

Nitric acid	5-10 ml
Distilled water	to 100 ml.

Procedure

1. Place calcified specimen in large quantities of nitric acid solution until decalcification is complete (change solution daily for best results).
2. Washing running water for 30 minutes
3. Neutralize for a period of at least 5 hours in 10% formalin to which excess of calcium or magnesium carbonate has been added.
4. Wash in running water over night
5. Dehydrate, clear and impregnate in paraffin or process as desired.

Note: Overexposure to nitric acid impairs nuclear staining. Nitric acid is the solution of choice for decalcifying temporal bones.

Perenyi's fluid

10% nitric acid	40.0ml
Absolute alcohol	30.0 ml.
0.5% chromic acid.	30.0 ml.

Note all these ingredients may be kept in stock and should be mixed immediately before use. This solution may acquire of blue violet tinge after a short while but this will have no effect in the decalcifying property.

It is slow for decalcifying hard bone but excellent fluid for small deposits of calcium eg. calcified arteries, coin lesions and calcified glands. Also good for human globe which contains calcium due to pathological conditions. There is little hardening of tissue but excellent morphologic detail is preserved.

Formalin Nitric acid

Formalin	10 ml
Distilled water	80 ml
Nitric acid	10ml

Nitric acid causes serious deterioration of nuclear stainability which partially inhibited by formaldehyde. Old nitric acid also tends to develop yellow discolouration which may be prevented by stabilization with 1% urea.

Aqueous formic acid

90% formic acid	5-10 ml
Distilled water	to 100 ml.

Gooding and Stewart's fluid.

90% formic acid	5-10ml.
Formalin	5ml
Distilled water	to 100 ml.

Evans and Krajian fluid

20% aqueous trisodium citrate	65 ml
90% formic acid	35 ml

This solution has a pH of - 2-3

Formic acid sodium citrate method

Procedure

1. Place calcified specimen in large quantities of formic acid-sodium citrate solution until decalcification is complete (change solution daily for best results).
2. Wash in running water for 4-8 hours
3. Dehydrate, clear and impregnate with paraffin or process as desired.

This technique gives better staining results than nitric acid method, since formic acid and sodium citrate are less harsh on the cellular properties. Therefore even with over exposure of tissue in this solution after decalcification has been complete, causes little loss of staining qualities. This method of choice for all orbital decalcification including the globe.

Surface decalcification- The surface of the block to be decalcified is trimmed with scalpel. The block is then placed in acid solution at 1% hydrochloric acid face downwards so that acid bathes the cut surface for 15-60 min. As penetration and decalcification is only sufficient for a few sections be cut the block shall be carefully oriented in microtome to avoid wastage of decalcified tissue.

Methods and Protocols for Decalcification of Bone Material

Calfor and XL-Cal Immuno Bone Decalcifier

Fixation: 10% Buffered Neutral Formalin for up to 5 days.

All fixed specimens are washed in slowly running tap water for a minimum of 30 minutes. Larger specimens are washed up to a maximum of 1 hour. Avoid rinsing in rapidly running water.

Solutions:

8% Hydrochloric Acid Stock Solution:

Hydrochloric acid, concentrated ----- 40 ml

Distilled water ----- 460 ml

Mix well and store at room temperature.

8% Formic Acid Stock Solution:

Formic acid ----- 40 ml

Distilled water ----- 460 ml

Mix well and store at room temperature.

Hydrochloric Acid/Formic Acid Working Solution:

Combine equal parts of the 8% hydrochloric acid solution and the 8% formic acid solution before use.

Ammonia Solution:

Ammonia, Concentrated ----- 5 drops

Distilled water ----- 100 ml

Mix well

Procedure:

1. Specimens should be decalcified in hydrochloric acid/formic acid working solution 20 times their volume.
2. Change to fresh solution each day until decalcification is complete. It may take 24 hours up to days or months depending on size of the specimens. See below for the testing procedures **(Decalcification for rabbit spine using this protocol for overnight about 20 hours and it showed very good result)**
3. Once the decalcification is complete, rinse specimens in water briefly and transfer to ammonia solution to neutralize acids left in specimens for 30 minutes.
4. Wash specimens in running tap water thoroughly up to 24 hours.
5. Routine paraffin embedding.

Specimens should **NOT** be crowded together and should **NOT** contact the bottom of container in order to provide for complete decalcification.

Overdecalcification can also permanently damage a specimen. The following procedure help determine the correct end-point of decalcification.

End-Point of Decalcification:

X-ray (the most accurate way)

Chemical testing (accurate)

Physical testing (less accurate and potentially damage of specimen)

Chemical Test:

The following solutions are needed to chemically test for residual calcium.

5% Ammonium Hydroxide Stock:

Ammonium hydroxide, 28% ----- 5 ml

Distilled water ----- 95 ml

Mix well

5% Ammonium Oxalate Stock:

Ammonium oxalate ----- 5 ml

Distilled water ----- 95 ml

Mix well

Ammonium Hydroxide/Ammonium Oxalate Working Solution:

Use equal parts of the 5% ammonium hydroxide solution and the 5% ammonium oxalate solution.

Procedure:

1. Insert a pipette into the decalcifying solution containing the specimen.
2. Withdraw approximately 5 ml of the hydrochloric acid/formic acid decalcification solution from under the specimen and place it in a test tube.
3. Add approximately 10 ml of the ammonium hydroxide/ammonium oxalate working solution, mix well and let stand overnight.
4. Decalcification is complete when no precipitate is observed on two consecutive days of testing. Repeat this test every two or three days.

Physical Tests:

The physical tests include bending the specimen or inserting a pin, razor, or scalpel directly into the tissue. The disadvantage of inserting a pin, razor, or scalpel is the introduction of tears and pinhole artifacts. Slightly bending the specimen is safer and less disruptive but will not conclusively determine if all calcium salts have been removed. After checking for rigidity, wash thoroughly prior to processing.

Note: If paraffin embedded bones were not decalcified fully, one can soak the paraffin blocks in the same decalcification solution for a few minutes before cutting. This is usually helpful.

Decalcification of Bone marrow biopsy.

Tissue after fixation in Bouin's or Zenker's fixative is decalcified for 2½ hours followed by an hour of washing. The tissue is then dehydrated beginning with alcohol.

Use of Ion exchange resins

Ion exchange resins in decalcifying fluids are used to remove calcium ion from the fluid. Therefore ensuring a rapid rate of solubility of calcium from tissue and reduction in time of decalcification. The resins are an ammoniated salt of sulfonated resin along with various concentrations of formic acid are used.

The resin is layered on the bottom of a container to a depth of = ½ inch, the specimen is allowed to rest in it.

After use, the resin may be regenerated by washing twice with dilute N/10 HCL followed by three washes in distilled water. Use of ion exchange resin has advantage of (i) faster decalcification (ii) tissue preservation and (iii) cellular details better preserved.

Chelating agents

Chelating agents are organic compounds which have the power of binding certain metals. Ethylene-diamine-tetra-acetic acid, disodium salt called Versenate has the power of capturing metallic ions. This is a slow process but has little or no effect on other tissue elements. Some enzymes are still active after EDTA decalcification.

Versenate	10 gm.
Distilled water	100 ml
	(pH 5.5 to 6.5)
Time	7-21 days.

Electrolytic method

This is based on the principle of attracting calcium ions to a negative electrode in to addition to the solution.

Decalcifying solution

HCL (Conc.)	80ml
Formic acid 90%	100 ml
Distilled water	1000 ml.

Decalcify with electrolyte apparatus with the above mentioned decalcifying fluid. This method has no added advantage over any other method.

Neutralization : It has been said that following immersion in mineral acids, tissues should be deacidified or neutralized, before washing by treatment with alkali. This may be effected by treatment over night in 5% lithium or sodium sulphate.

Washing : Through washing of the tissue before processing is essential to remove acid (or alkali if neutralized has been carried out) which would otherwise interfere with staining)

Determination of end point of decalcification

1. Flexibility method

Bending, needling or by use of scalpel if it bends easily that means decalcification is complete.

Unreliable, causes damage and distortion of tissue.

2. X-ray method

Best method for determining complete decalcification but very costly. Tissue fixed in mercuric chloride containing fixatives cannot be tested as they will be radio opaque.

3. Chemical Method

It is done to detect calcium in the decalcifying fluid when no further calcium is detected, decalcification is considered complete.

Procedure

Take 5 ml of decalcifying fluid from the bottom of container which has been in contact with the tissue for 6-12 hrs. Add 5 ml each of 5% ammonium oxalate and 5% ammonium hydroxide. Mix and let it stand for 15-30 min. A cloudy solution caused by calcium oxalate indicates that specimen is not thoroughly decalcified. Absence of turbidity indicates completeness of decalcification.

Treatment of hard tissues

Keratin and chitin are softened by use of concentrated sulphuric and with that aid of heat keratin is completely dissolved from the tissue sections. But much tissue distortion will also occur.

For softening of chitin foll procedure gives a satisfactory result.

1. Fix the specimen in fixative of choice.
2. Place the specimen in following solution until complete dechitinized.
Change the solution every two days for best results.

Mercuric chloride	-	4 gm
Chromic acid	-	0.5gm
Nitric acid (Conc.)	-	10.0ml
Ethyl alcohol 95%	-	50.0 ml
Distilled water	-	200.0ml

3. Washing running water for 3 hours
4. Dehydrate, clear and impregnate with paraffin.

Prenyi's fluid

Immersing hard tissues in this solutions for 12-24 hours will make sectioning easier and excellent preparation of calcified arteries, thyroid and calcified glands is possible.

Lendrum's technique

It is very useful for tissues which became hard at the time of fixation. Following washing out of the fixative, tissue is immersed in a 4% aqueous solution of phenol for 1-3 days.

Wax blocks - The treatment of wax embedded block of hard tissue may be done by soaking in soap water overnight.

CHAPTER : 4

TISSUE PROCESSING

Specific objective - The tissue processing is the heart of any tissue section which will be cut adequately only if the tissue is properly preserved and processed. The study of this topic is to understand the coarse and fine details of tissue processing so that excellent sections are obtained.

Mode of teaching - Overhead projector, slide projector and practical demonstration.

Definition - The term tissue processing refers to treatment of the tissue necessary to impregnate it into a solid medium so that the tissue is rendered sufficiently firm yet elastic for the tissue sections of desirable thickness to be cut on microtome.

This is not the only technique employed for tissue sections. Sections can also be produced by means of cryostat or freezing microtome on frozen tissues.

The fixed impregnated tissues have an advantage that they can be more easily stored and reproducibility of sections at a later date is easier.

Before proceeding on tissue processing as soon as the tissue is received it is very important that the tissue be properly labeled so as to avoid any confusion regarding duplication of same name or giving a wrong diagnosis to the patient.

The *labeling* has to be a full proof system.

The label should remain throughout the entire processing and later as

permanent record keeping. To ensure this most laboratories have a numbering system for each specimen. As soon as the specimen is received it is given a specific individual number, which is also recorded in the register with the details like patient's name, name of the doctor referring it, nature of tissue is noted.

Labeling should not be done using ordinary ink as it gets dissolved in the reagent used during processing.

Thin white card with a soft lead pencil, typed or printed labels are satisfactory. To ensure that the label remains with their correct specimens tissues processing baskets can be used. These are small perforated metal containers in which the tissue and labels are placed. these containers can be transferred as such from reagent to reagent.

Alternatively use of tissue tek system in which the tissue identity is written on the cassette and retained as permanent record during sectioning and storage of tissue blocks.

Principle of tissue processing - The tissue is embedded in a solid medium by the help of first removing the tissue water which is then replaced by any solid medium such as paraffin wax so that the tissue is rendered firm enough to enable thin sections to be cut, at the same time, the tissue is soft (not so hard) to enable microtome knife to cut the sections.

The embedding medium has to thoroughly permeate the tissue in fluid form so that it solidifies without any damage to the tissue. The most satisfactory embedding medium used in routine histology is paraffin wax. Most of the tissue fixatives are aqueous fixatives so before the tissue can be

embedded in paraffin wax it is necessary that the water and some of the lipid tissue fluids be removed completely by a variety of compounds through a process called **dehydration**.

Prior to paraffin wax embedding and impregnation the tissue must be subjected to the following steps:

1. Fixation
2. Dehydration -
3. Clearing - with a substance which is totally miscible with both the dehydrating agent which precedes it, and embedding agent which follows it.
4. Embedding

All these 4 processes depend upon complete impregnation of the tissue by the agent like paraffin wax being used.

Before going into the details of these 4 stages it is important to understand the factors which influence the rate and efficiency of tissue impregnation

Factors influencing the rate of impregnation

A tissue immersed in fluid interchange occurs between tissue fluid and surrounding fluid. The process continues through all stages of processing from fixation to final impregnation.

Agitation - Tissue placed in liquid is agitated so that the fluid immediately in contact with the surface of tissue which is mixed by tissue fluid is replaced by the fresh immersing liquid.

This can be achieved by a pumping system which removes and replaces fluid at selected intervals or by rotation and vertical oscillation method. Efficient agitation reduces the processing time by 25-30% with improved impregnation of the tissue.

Heat - Heat increases the rate of penetration.

Viscosity - Larger the molecule the higher is the viscosity slower is the rate of penetration.

Ultrasonic : Use of ultrasonics increases the penetration rate.

Vacuum : Use of reduced pressure is well known in the impregnation of tissue by molten paraffin wax. It hastens the process. Use of vacuum during dehydration and clearing has little advantage except removal of air bubble trapped within the tissue.

STEPS OF PARAFFIN WAX EMBEDDING **Fixation** - Usually tissue that is received at the laboratory is already fixed but before proceeding further check if the fixation is complete.

Dehydration - After fixation in aqueous solvent the delicate tissue needs to be dehydrated slowly starting in 50% ethyl alcohol. The other routine tissue specimen may be put in 70% alcohol. A higher concentration of alcohol initially is inadvisable because this may cause very rapid removal of water may produce cell shrinkage. An exception to this is in case of Heidenhain's Susa fixed tissue where it may be placed directly in 95% alcohol. Tissue transferred from alcoholic based fixative like Carnoy's fixative may be placed in higher grades of alcohol or even in absolute alcohol.

For routine biopsy and postmortem tissue of 4-7 mm thickness 70%, 90% and absolute alcohol (2-3 changes for 2-4 hours each) are sufficient to give reasonably satisfactory result.

Use of solid dehydrants

Anhydrous copper sulphate is used in higher grade of dehydrating alcohols. A layer 1-2.5 cm thick is placed at the bottom of a dehydrating vessel or beaker and is covered with 2 or 3 filter papers to prevent contamination of the tissues. Anhydrous copper sulphate is white, it removes water from alcohol which in turn has been diluted upon absorption of water from the tissues. The change of colour of copper sulphate from white to blue indicates that both alcohol and water should be changed. Use of copper sulphate enhances the process of dehydration and also prolongs the life of alcohol.

Other dehydrating agents

1. Acetone - It is clear, colourless volatile inflammable fluid.
 - ☐ It has a rapid action in dehydrating the tissue but produces shrinkage and distortion and subsequent brittleness to the tissue.
 - ☐ Low cost is also an advantage.

Acetone usually dehydrates within 20-30 minutes but four changes of acetone should be used, it is preferable to use acetone after low strength of alcohol so that distortion of the tissue is less.

2. Dioxane - It dehydrates and clears at the same time. It is miscible with paraffin and with water and alcohol, tissue from dioxane can be transferred straight to paraffin.

- ☐ There is less shrinkage of tissues
- ☐ Tissues can be left in dioxane without danger of hardening for longer period of time.

Disadvantage: It is more expensive than alcohol.

* It is toxic to man

3. Isopropyl alcohol

- ☐ It is miscible with water and other organic solvents
- ☐ It does not harden the tissue like alcohol
- ☐ It is expensive

Clearing

Definition - Clearing means appearance of tissue after it has been treated by the fluid chosen to remove the dehydrating agent.

Most of these tissues have similar refractive index to that of protein therefore the tissue is left translucent.

Clearing agent is required when the dehydrating agent is not miscible with the impregnating medium. It is essential for a clearing agent to be miscible both in dehydrating agent as well as embedding agent.

Commonly used clearing agents are as follows :

1. *Xylene* - It has a rapid action. Biopsy specimens of 3-4 mm thickness are cleared in 2-4 hours.

Immersion time must not be prolonged otherwise the tissue become brittle.

2. *Toluene and Benzene* are similar in properties to xylene but are less damaging to the tissues on prolonged exposure.

3. *Chloroform* - It is slower in action but it causes less brittleness therefore tissue can be left in it overnight.

- ☐ It does not affect the refractive index of the tissue is not rendered translucent.

- ☐ It is expensive.

- ☐ It is inflammable.

4. *Carbon tetrachloride* - It has similar properties to chloroform but is cheaper.

5. *Cedar wood oil* (Histological): It is good for treatment of delicate tissues as it has the least hardening effect.

- ☐ It is very slow in action.

- ☐ It is very expensive.

Care should be taken not to confuse it with cedar wood oil (microscopic) used with oil immersion lens.

Techniques of clearing : If the tissue is being cleared in chloroform or carbon tetrachloride it may be left overnight. In automatic tissue processor three changes of one hour each are usually satisfactory.

In Xylene, benzene or toluene one change after 30-60 minutes is satisfactory to give a clear translucent appearance to the tissue.

Impregnation

Definition - It is the complete removal of clearing reagents by substitution of paraffin or any such similar media.

Impregnation with wax

Impregnation with paraffin wax takes place in an oven heated to 56-60°C depending upon the melting point of the wax in use.

Frequent check of the temperature of paraffin baths is required since temperature 5°C above the melting point of the paraffin will cause tissue shrinkage and hardening.

Properties of paraffin wax

1. Easy to prepare large number of tissue blocks in comparatively short time.
2. Minimum supervision is required
3. It is cheaper than other impregnating media
4. During staining there is very little difficulty than other media.

Points to be remembered during use of paraffin wax

1. It should be free from dust, grit and other foreign matter.
2. It should not contain water, which causes it to crystallize and turn it white.

3. The wax has to be filtered before use by use of ordinary filter paper.
4. Higher melting point waxes are hard to ribbon.

For impregnation the wax oven has to be kept at high temperature, making the tissue hard, too low melting point wax may not be hard enough to support the tissue during cutting. If the wax is overheated and remains in that state for a long time, it tends to crystallize and become useless.

Paraplast - This is mixture of highly purified paraffin and several plastic polymers.

It has greater elasticity than normal paraffin wax, therefore, the results are superior.

It ribbons well allowing almost wrinkle free serial sections to be cut with ease at 4 micron thickness.

It should not be used for thin walled structures as it prevents complete expansion of the specimen.

Bioloid - Good embedding medium in which thin walled structures can be sectioned satisfactorily.

Technique of impregnation : The tissue is transferred from clearing agent to molten paraffin wax. The amount of wax should be 25-50 times the volume of tissue. The tissue must be submitted to 3 changes in wax. The temperature of the wax bath should be 2-3°C above the melting point of wax.

Time of impregnation

Depends on the following 3 factors

1. The size and type of tissue
2. The clearing agent employed
3. The use of vacuum embedding oven.

1. Size and type of tissue:

The thicker the tissue the longer will be the time required for wax to penetrate to the centre in addition a thick tissue has more of clearing agent so more changes of wax are necessary to remove it. If even small amounts of clearing agents remains with the wax this will cause crystallization and produce crumbling of the sections during cutting.

The type of tissue is also important since bone, skin, CNS needs twice as long as soft tissue like liver or kidney.

Tissue like muscle and fibrous tissue tends to overharden and become brittle in wax bath so the time for impregnation must be kept to a minimum. The reduction of time can be achieved by using vacuum embedding medium.

2. Clearing agent employed

Some clearing agents are more rapidly and easily cleared than other e.g. Xylene, benzene and toluene are easiest to remove, and one change of wax is normally sufficient; whereas for chloroform and carbon tetrachloride 2-3 changes are needed.

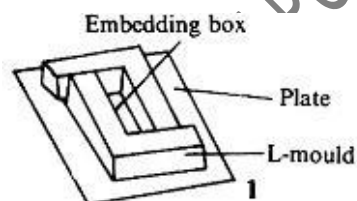
3. Use of vacuum embedding oven

With the use of normal paraffin oven, 2 changes of paraffin wax for a period of 4 hours are needed but by using vacuum embedding oven this time may be halved

Embedding - It is the orientation of tissue in melted paraffin which when solidified provides a firm medium for keeping intact all parts of the tissue when sections are cut.

Types of moulds

- a) Leuckhart's L pieces - These are two 'L' which are resting metal usually brass, which are resting on a flat metal or glass plate.



1. L moulds or embedding box

- b) Compound embedding units - consists of square shaped brass or metal plates in a series of interlocking plates.
- c) Others like plastic embedding blocks (tissue Tek system)

Techniques of casting

- 1. Molten paraffin wax which is heated at a temperature 2-3° above the melting point is poured into the mould to an adequate depth so as to cover the thickest tissue block.

2. The wax touching the mould will quickly form a thin semi solid layers, Now introduce the tissue with a prewarmed forceps to prevent the wax to stick to it. The tissue is pressed in this semisolid wax to orient it at the bottom of mould in a correct plane.
3. Fix the label in position by pressing one edge against solidifying wax usually sides of the mould are preferred.
4. As soon as a film of solid wax is formed on the surface, the whole block with mould are submerged in cold water at 20°C. If this is not done there will be crystallization of wax, using ice water to do initial cooling will also cause the block to crack.
5. When blocks are set hard they are removed from mould.

The tissue surface towards the mould base is from where the sections are to be cut this surface should be trimmed lightly with a scalpel so as to expose the tissue.

Following points must be taken care off during casting.

1. Paraffin should not be allowed to cool around the tissue to be blocked for this before introducing the tissue in the mould it should be kept in heated wax or in cassette placed over thermostatic hot plate.
2. To prevent excess of wax solidifying on the bottom of the block during winter prewarmed moulds may be used.
3. The cutting surface of the tissue should be facing at the bottom of the mould.

4. If 2 or more tissues have to be casted remember to keep them both at the same depth.
5. If small biopsy fragments have to be casted, the largest piece should be first blocked and other pieces should be as near it as possible.
6. All four corners of the block should be in one horizontal plane.
7. The tissue should have atleast 2 mm wax around its edges.
8. Smear mineral or machine oil on the inner surface of the mould for facilitating easy removal of block.
9. Whitish areas around tissue in block denotes crystalization which may be due to moisture or due to incomplete removal of clearing agent.

Most tissue sections are cut from the largest area but some tissue needs special mention.

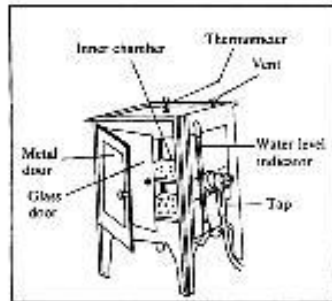
1. Tissue of tubular nature are cut transversely so should be embedded vertically.
2. Skin is cut in a plane at right angles to the surface so should be embedded at right angles to the bottom.
3. Muscle biopsy should be sectioned in both transverse and longitudinal planes.

Automatic tissue processor

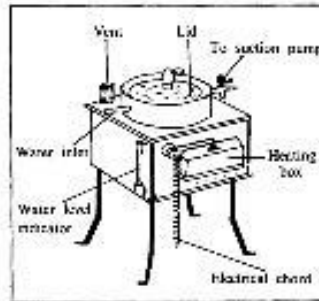
It has 2 advantages

1. Transferring the tissue mechanically from one reagent to another can be done both by day and night.

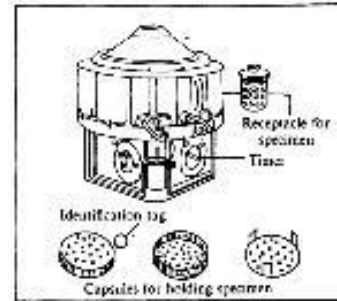
2. Reduces processing time by the action of continuous agitation.
3. This eliminates the possibility of human errors of leaving the tissue for long time in one solution due to forgetfulness.



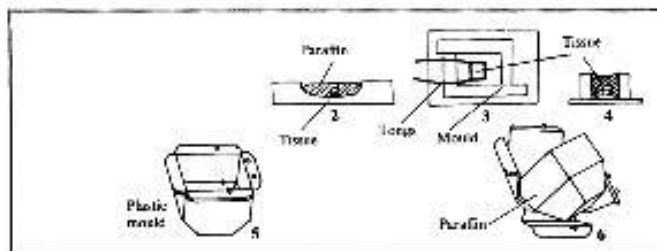
Components of paraffin embedding oven



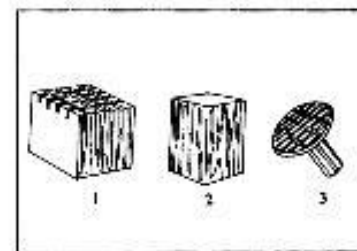
Components of vacuum paraffin embedding bath



Automatic tissue processor



Paraffin embedding (2-4) The process of tissue embedding in L-mould
(5) Plastic mould and (6) Paraffin block



Object carriers: (1) used for attachment of tissue
(2) steel rectangular wooden block with grooved face and plane (3) Metal object carrier

VARIOUS PARTS OF THE MACHINE ARE AS FOLLOWS

- (a) Tissue containers - These are also the cassettes. The tissue to be processed is placed in an appropriate container, together with a label and the lid snapped on. These containers are placed in the tissue basket in which they remain throughout the whole process.
- (b) Beakers and wax baths - Most machines are equipped with ten beakers and 2 wax baths thermostatically controlled at $56^{\circ}\text{C} + 4^{\circ}\text{C}$. The beakers are filled with appropriate fluids and wax is placed in the wax baths after ensuring that main switch is on, so as to keep the wax in molten state.

- (c) Stirring mechanism - The basket is attached to the arms of the machine on which one arm is designed in such a manner so as to bring about the rotation of the basket nearly at the rate of one revolution per minute.
- (d) Timing mechanism - Timer is meant to keep the tissue in different reagents and wax for an optimum time. If kept for longer or shorter period than necessary, tissue will not be adequately processed.

Points to noted

1. Fluid and wax beakers must be filled upto appropriate mark and located in their correct position in the machine.
2. Any spillage of the fluid should be wiped away.
3. Accumulations of wax must be removed from beaker, covers, lids and surrounding areas.
4. Wax bath thermostats should be set at satisfactory levels usually 2-3°C above the melting point of wax.
5. Particular attention should be paid to fastening the processing baskets on the crousel type of machines, if the baskets are shed they will remain in one particular reagent for a long period till it gets noticed.
6. Timing should be set with utmost care when loading the machine.
7. Paraffin wax baths should be checked to ensure that the wax is molten.

Automated processing schedule

1.	80% alcohol (holding point)	1 hours
2.	95% alcohol	2 hours
3.	95% alcohol	1 hour
4.	100% alcohol	1 hour
5.	100% alcohol	1 hour
6.	100% alcohol	1 hour
7.	Chloroform	1 hour
8.	Chloroform	1 hour
9.	Chloroform	1 hour
10.	Paraffin wax	2 hours
11.	Paraffin wax	2 hours
12.	Paraffin wax	2 hours

Note : Keep watch on paraffin temperature

- ☐ Tissue should not be left in any solution for a longtime
- ☐ Frequent filtration and changes of solution are needed

Schedule for hard & delicate tissues

1.	80% alcohol two changes	1 hour each
2.	95% alcohol two changes	1 hour each
3.	Absolute alcohol three changes	1 hour each
4.	Absolute alcohol and xylene equal parts	1 hour
5.	Cedar wood oil 2 changes	2 hours each
6.	Cedar wood oil 1 change	1 hour
7.	Paraffin wax one change	2 hours
8.	Paraffin wax four changes	1 hour each

Vacuum the last paraffin change. Embed and cool quickly. Cut as desired.

Processing schedule for skin

- | | | |
|----|------------------|------------|
| 1. | 70% alcohol | 1 hour |
| 2. | 95% alcohol | 2 hours |
| 3. | Absolute alcohol | 2 hours |
| 4. | Absolute alcohol | 3 hours |
| 5. | Cedar wood oil | over night |
| 6. | Xylene | 20 minutes |
| 7. | Wax I | 3 hours |
| 8. | Wax II | over night |

Embedding wax local preparation in laboratory.

Method (A)

- | | | |
|----|-----------------------|-------|
| 1. | Paraffin wax (Candle) | 1 Kg. |
| 2. | Bees Wax | 25gm |

Melt and filter

Method (B)

- | | | |
|----|-----------------|---------|
| 1. | Paraffin wax | 1kg |
| 2. | Liquid paraffin | 5-10 ml |

Melt and filter. Find the ratio by experiment according to the melting point desired.

CHAPTER 5

SECTION CUTTING

Specific objective

1. To ensure good section cutting
2. To overcome troubleshooters during section cutting.
3. To familiarise the staff with the equipment used for section cutting.

Mode of teaching - Overhead projector and practical demonstration.

Introduction

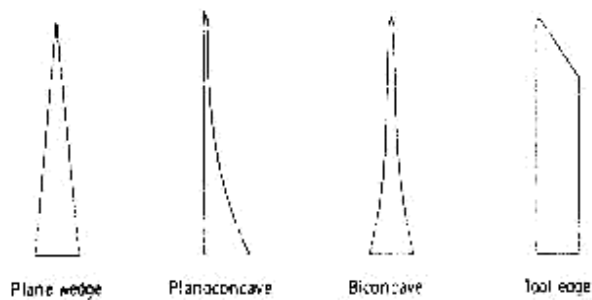
To master in the art of good section cutting it is required

1. To have a thorough knowledge of the equipment used.
2. Quality of equipment
3. Quality of processing the tissue.

Microtome Knives : The knife is probably the greatest single factor in producing good sections.

Types of microtome knives : Microtome knives are classified by the manner in which they are ground and seen in their cross section.

1. Plane wedge
2. Plano concave
3. Biconcave
4. Tool edge



Plane wedge : It is used for paraffin and frozen sections.

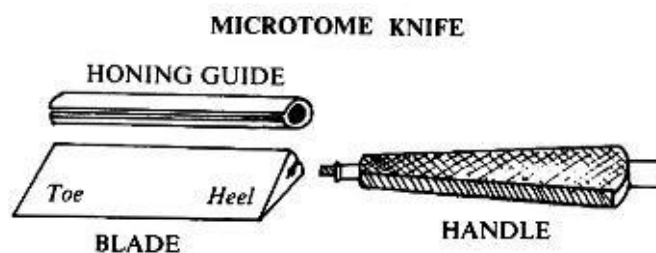
Planoconcave : used for celloidin section since the blade is thin it will vibrate when for used for other harder materials.

Biconcave : It is recommended for paraffin section cutting on rocking and sledge type of microtome.

Tool edge : This is used with a heavy microtome for cutting very hard tissues like undecalcified bone.

General description

In the description of knives the expressions “Heel” and “Toe” are used to indicate to indicate which end of the cutting edge is referred to. The heel of the knife is the angle formed by the cutting edge and the end of the knife nearest to handle. The “toe” of knife is the angle formed by the cutting edge and the end of the knife farthest from the handle.



Sharpening of microtome knives

The cutting edge of an ideal microtome knife is a straight line formed by intersection of 2 planes, the cutting facets. The angle between the planes is called the bevel angle and is greater than the wedge angle between the sides of knife. The standard microtome knife has a wedge angle of approximately 15° and bevel angle varying between 27° and 32° .

Honing

Definition - Grinding of knife on a hone to restore straight cutting edge and correct bevel.

There are various types of hones

1. Belgian black vein or Belgian yellow

It is a yellow stone $\frac{1}{2}$ inch thick and is backed with a black stone of same thickness. Only yellow side should be used for honing. It is the best hone. It is quite a fast hone and may be used for coarse grinding and finishing.

2. Arkansas – Not very fast.
3. Aloxide – Fairly fast but coarse and not good for finishing a knife.
4. Carborundum – These hones can be obtained in a variety of grades only the finest of which should be used that too for coarse work.
5. Plate glass – May be used as a hone by applying an abrasive such as aluminium oxide to the surface and then using in the same way as ordinary hone.

The advantage of such a hone is that it can be used for all types of honing by changing the abrasive powder.

Lubricants for hone

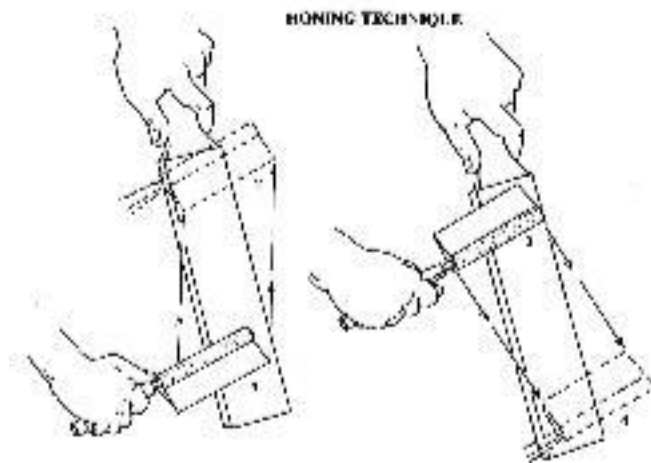
1. Soap water
2. Liquid paraffin
3. Castor oil
4. Clove oil

Method of honing

1. The hone is placed on a bench on a nonskid surface.
2. A small quantity of light lubricant oil is poured on the centre of the hone and lightly smeared over the surface.
3. The knife complete with handle and backing sheath is laid on the hone with the cutting edge facing away from the operator, and the heel in the centre of the nearest end of hone. Correct positioning of the fingers is achieved by holding the handle of the knife between the thumb and forefinger with the cutting edge facing away from the operator (so that the thumb is on the back). When the knife is on the hone the tips of finger and thumb of other hand rest on the other end of knife ensuring even pressure along the whole edge of knife during honing.
4. The knife is pushed forward diagonally from heel to toe, turned over on its back and moved across the hone until the heel is in the centre

with the cutting edge leading, and then brought back diagonally. It is turned to its original position, thus completing figure of 8 movement.

5. The process is continued until all jagged edges have been removed. The knife is ready for stropping.



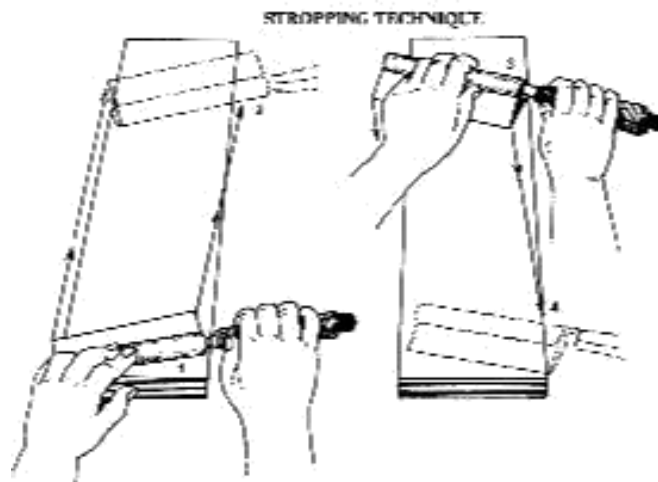
Stropping

Definition : It is the process of polishing an already fairly sharp edge. It removes burrs formed during honing.

Fine quality leather is used leather strops may be either flexible / hanging or rigid. In stropping usually firm surface is preferred. Action is reverse of honing toe to heel direction of stropping is also opposite.

Assessment of the sharpened knife edge.

Examine the edge the knife by reflected light and under microscope to assess the honing and stropping.



Care of the knife

1. Keep the knife covered in the box when not in use.
2. Oil the knife to prevent corrosion.
3. Always clean knife with xylol rag before and after use.
4. It should always be stropped before use.
5. Knife should be sharpened as and when required.

Automatic microtome knife sharpeners

There are many automatic knife sharpeners available Shandon type is most commonly used which consists of a glass plate on which fairly coarse abrasive powder like alumina powder is applied. First matting is done followed by lapping to remove all finer scratches.

In all stages of use of abrasive powder care must be taken to remove by thorough washing any traces of abrasive powder from both knife and plate.

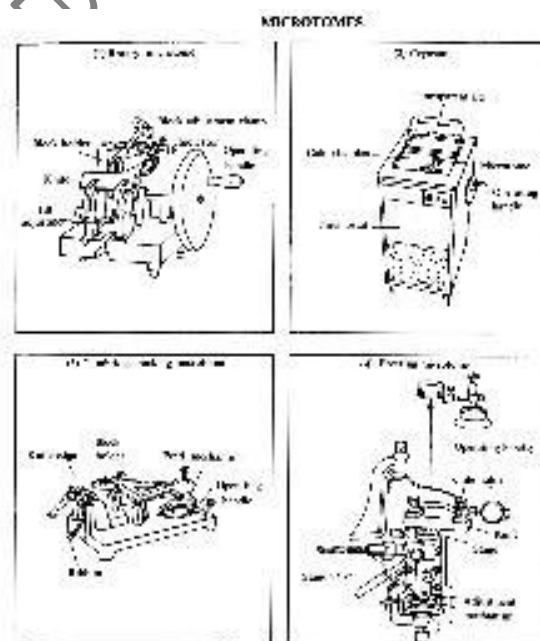
Microtomes

These are mechanical devices for cutting uniform sections of tissue of appropriate thickness. All microtomes other than those used for producing ultra thin sections for electron microscopy depend upon the motion of a screw thread in order to advance the tissue block on knife at a regulated number of microns.

Motion of screws can be direct or through system of gears or levers to magnify the movement.

Types of microtome

1. Hand microtomes – limited for use in botanical sections
2. Rocking microtome
3. Rotary microtome
4. Freezing microtome
5. Base sledge microtome
6. Vibrating knife microtome



Size of Knives

110 mm Knife	-	Frozen sections
120 & 185 mm	-	Routine paraffin block

Paraffin section cutting

Equipment required

1. Microtome
2. Water bath preferably thermostatically controlled.
3. Hot plate or drying oven thermostatically controlled.
4. Fine pointed forceps.
5. Small hair brush.
6. Seeker
7. Scalpel
8. Clear cloth or paper towel.
9. Slide rack
10. Clean glass slides
11. Section adhesive
12. Fluff less blotting paper
13. Ice cubes
14. Diamond marker pencil

Water bath. Thermostatically controlled for paraffin wax of melting point 56°C, a water temperature of 45°C is sufficient ordinary distilled water is satisfactory; addition of a trace of detergent to water is beneficial in flattening of sections.

Hot plate or drying oven

Drying of sections at around the melting point of wax is satisfactory

Brush, seeker, forceps – needed to remove folds and creases in sections after floating out.

Slides - Majority of sections fit comfortably on a 76 x 25 x 1.2 mm slide.

Diamond pencil – needed to write the identification details like name or specific number.

Section adhesives

An adhesive is a substance which can be smeared on to the slides so that the sections stick well to the slides.

Most of the tissue sections which are adequately thin and thoroughly dried without any air bubble trapped under them do not require an adhesive, as in case of routine H and E staining, but for histochemical methods requiring alkaline solutions eg ammonia tend to remove sections from slide for such cases adhesive is required. Also adhesive is required for tissues like brain, spinal cord, blood clot, decalcified tissues which have a tendency to detach themselves from the slide. Tissue impregnated with ester wax also require section adhesive.

Types of adhesive

Albumin

Gelatin

Starch

Cellulose

Sodium silicate

Resin

Poly L Lysine

Adhesive are either added to water bath or smeared thinly on slide.

1. Agar – add 50 ml of melted agar to water bath
2. Gelatin – Add 30 ml of melted gelatin to water bath
3. Mayer's glycerol albumin – This is the most popular adhesive for routine use :

- | | |
|----------------------|-------|
| 1. Fresh egg white | 50 ml |
| 2. Glycerol | 50 ml |
| 3. Sodium salicylate | 1 ml |

Mix and agitate the ingredients filter through coarse filter paper smear fluid over the slide. This fluid may be diluted 1:20 with distilled water and section floated on the fluid, while manipulating the albuminized slide under water in the floatation bath to pick up the section, avoid dipping the entire slide as the albumin may wash off.

Section cutting of paraffin embedded tissue

Fixing of block

1. Fix the block in the block holder on the microtome knife in such as position that it will be clear of the knife when it is in position, block may be fixed directly or it may be fixed to a metal carrier which in turn is fixed to the microtome.

2. Insert the appropriate knife in the knife holder and screw it tightly in position. Adjust if required. The clearance angle should be set at 3-4 degree and angle of slope should be set permanently at 90 degree. It is important to tighten the knife clamp screw securely and block clamp screws must also be firm.

The exposed ends of the knife must all the times be protected by magnetic or clip on knife guards to avoid any accidents.

3. *Trimming of tissue block* : Move the block forward so that the wax block is almost touching the knife. To trim away any surplus wax and to expose a suitable area of tissue for sectioning, the section thickness adjusters are set at 15 microns.
4. On exposing a suitable area of tissue the section thickness is set to the appropriate level for routine purposes to 4-6 microns.
5. Apply ice to the surface of the block for a few seconds and wipe the surface of block free of water. This step is optional but makes sections cut easily.
6. Note that the whole surface of the block will move parallel to the edge of the knife in order to ensure a straight ribbon of sections.
7. The microtome is now moved in an easy rhythm with right hand operating the microtome and left hand holding the sections away from the knife. The ribbon is formed due to the slight heat generated during cutting, which causes the edges of the sections to adhere. If difficulty is experienced in forming the ribbon it is sometimes overcome by rubbing one of the edges of the block with finger.

8. During cutting the paraffin wax embedded sections become slightly compressed and creased. Before being attached to slides the creases must be removed and the section flattened. This is achieved by floating them on warm water. Thermostatically controlled water baths are now available with the inside coated black. These baths are controlled at a temperature 4-6°C below the melting point of paraffin wax. It is easy to see creases if the inside of water bath is black.
9. The action in floating out must be smooth with the trailing end of ribbon making contact with water first to obtain flat sections with correct orientation, floating out with the shiny surface towards the water is essential. When the ribbon has come to rest on water the remaining wrinkles and folds are removed by teasing apart by using forceps or seeker.
10. *Picking up sections* – The ribbon of sections floating on water is split into individual or groups of sections by use of forceps or seekers. Picking up a section on slide is achieved by immersing the slide lightly smeared with adhesive vertically to three fourths of its length bringing the section in contact with the slide. On lifting the slide vertically from the water, the section will flatten on to the slide. The sections are then blotted lightly with moistened blotting paper to remove excess water and to increase contact between section and slide. For delicate tissues or when several ribbons of sections are placed on the slide, omit the blotting instead keep the slide in upright position for several minutes to drain.

11. *Drying of section* : Sections are then kept in incubator with a temperature 5-6°C above the melting point of wax i.e. at 60°C for 20-60 minutes. It is better to overheat than underheat. If the sections are not well dried they may come off during staining.

The sections should not be allowed to dry without a good contact with the slide ,such sections will come off during staining.

SOME USEFUL HINTS IN SECTION CUTTING

Methods of removing bubbles trapped beneath the sections

Bubbles may get trapped under a section while in the tissue flotation bath. These need to be removed before the section are picked on the slides this may be done by:

1. With the edge of slide.
2. Can be teased out with bent dissecting needle.
3. Place the sections on slide and run 2% alcohol under them. Any fold or bubbles are removed.

To cut a tissue which has a tendency to crumble or fragment while cutting.

With the mouth open and sounding a soft long drawn 'H' thus 'h h h h h ' exhale gently on to the section as it leaves the knife and cut very slowly.

This also helps to reduce the effect of static electricity.

If sections fragment due to large amount of blood in tissue, the block should be coated with celloidin between sections. The surface of the block should be wiped dry, and painted with a camel hairbrush which has been

dipped in 1% Celloidin. After allowing few seconds for the Celloidin to dry a section is cut in usual way.

It must be remembered that when floating the sections to remove the creases, the celloidin layer must be uppermost, and the water should be a little hotter than usual to counteract the effect of celloidin. Following drying in usual way, the celloidin is removed with equal parts of ether and alcohol before removing wax with xylol.

Serial sectioning

Serial sectioning may be needed to study the track of some structures or to find the extent of a lesions.

Sections are collected from the very first cut that includes any tissue. Ribbons of ten - 1-10, 11-20, 21-30 so on are picked up and mounted on the slides.

Step sections

This is an alternative for serial sections and for the same reason.

Sections are taken at periodic level through the block. The request is made for every n^{th} section for a total of 'n' sections.

Intermittent sections or sections on either side of each step sections for a total of 'n' sections.

Cooling block and knife. In general keep ice cubes ready at hand and cool the surface of block and knife before cutting, always dry and block and knife and block after the application of knife.

Trouble shooting for poor sections

There are times when proper section cannot be cut. Main reasons are either:

4. Faults occurring during section cutting or
5. Faults due to poor processing.

Below are given the various defects, reasons for the defect and the remedy for the same.

Faults in cutting

1. Fault - Tear or scratch across the section or splitting of ribbon. Cause - Jagged knife edge
Dirt or hair on knife edge.
Remedy- Sharpen the knife
Clean the knife
2. Fault - Tear or scratch across part of section,
Cause -Calcium, Carbon, or Suture etc., in the tissue or wax
Remedy- Examine block under magnifying glass. If calcium is present, decalcify block. Remove suture from the tissue with scalpel point. If dust is in wax - Re-embed
3. Fault - Holes in the section.
Cause -Air bubbles in the tissue or wax A piece
of hard material in tissue A soft
piece of tissue in block
Remedy- Re-embed
Remove hard material if possible
Reprocess specimen
4. Fault - Cracks across the section parallel to knife
Cause - A blunt knife

Knife tilt too small.

Block too hard for thickness of specimen

Remedy- Sharpen knife

Adjust tilt

Warm block slightly or re-embed in soft wax.

5. Fault - Section shows thin and thick horizontal lines (chatters)

Cause - A loose knife

A loose block

A blunt knife

Extremely hard tissue

Remedy- Tighten knife and/or block

Sharpen the knife

Soften the tissue if possible or embed in harden wax.

6. Fault - section cut thick and thin alternative

Cause - Knife tilt is too great and is compressing the block

Remedy Adjust tilt.

7. Fault - Section compress at one

end. Cause - Blunt spot on the knife

A soft spot in the wax, due to presence of clearing agent

Remedy- Move block along the knife or sharp knife.

Re infiltrate tissue and re-embed

8. Fault - Section curves to one end.

Cause -Edge of block is not parallel to knife. A

dull spot on knife.

Remedy- Trim edges

Move block along knife or sharpen knife.

9. Fault - Section curl as the they are cut

Cause - Blunt knife
Sections too thick
Too much tilt to knife

Remedy- Sharpen knife
Adjust microtome
Correct the tilt

10. Fault - Sections lift from knife on upward travel of block

Cause - Blunt knife
Too much tilt to knife
A build up of wax debris behind knife
A greasy knife.

Remedy- Sharpen knife
Correct the tilt
Clean the knife

11. Fault - Knife bites deeply into block

Cause - A loose knife
A loose block

Remedy- Tighten the knife and block

12. Fault - The block no longer feeds towards knife

Cause - Forward feed mechanism had expired

Remedy- Release the safety locking catch, man back off feed
mechanism and readjust knife holder

13. Fault - Sections crumble on cutting

Cause - Knife is blunt

Wax is too soft; has crystallized due to slow cooling or contamination with water or clearing agent.

Defective processing e.g. incomplete fixation, dehydration, clearing or embedding.

Remedy- Sharpen knife.

Re-embed and block with fresh wax

Reprocess

14. Fault - Failure of block to ribbon Cause

- Block not parallel to ribbon

Paraffin too hard.

Knife tilted too much

Sections too thick

Remedy- Correct the alignment

Re-embed Correct

the tilt

Adjust the section thickness

Fault due to poor processing

1. Fault - The tissue is shrunken away from wax

Cause - Insufficient dehydration Remedy-

Reprocess

2. Fault - The tissue is too soft when block is trimmed

Cause - Insufficient fixation

Remedy- Reprocess

3. Fault - Specimen crumbles and drops out of the wax leaving a rim of wax as a section

Cause -Insufficient infiltration

Overheated paraffin bath causing tissue to become hard and brittle

Remedy- Re infiltrate and re-embed

Service the paraffin bath

4. Fault - Tissue is dried out or mummified

Cause -Mechanical failure of tissue processing machine or a basket was out of balance and hung up.

Remedy- Place the specimen in the following rehydration solution for 18-24 hrs.

Sodium Carbonate - 1.0 gm

Dist. Water - 70.0 ml

Absolute ethyl alcohol - 30.0 ml

Re hydrate the reprocess

CHAPTER 6

STAINING

The sections, as they are prepared, are colourless and different components cannot be appreciated. Staining them by different coloured dyes, having affinities of specific components of tissues, makes identification and study of their morphology possible.

Certain terminologies used in the following account are given below.

Basophilic

Substances stained with basic dyes

Acidophilic

Substances stained by acid dyes

Vital staining

Staining of structures in living cells, either in the body (in vivo) or in a laboratory preparation (in vitro). e.g. Janus green is taken up by living cells and stains the mitochondria.

Metachromatic staining

There are certain basic dyes belonging to aniline group that will differentiate particular tissue components by staining them a different color to that of original dye. The phenomenon is known as metachromasia. The tissue elements reacting in this manner are said to be exhibiting metachromasia.

The generally accepted explanation of this phenomenon is that change in color is due to polymerization.

Sulfated substances are highly metachromatic e.g. Mast cell granules.

These contain Heparin which is highly sulfated.

Some of the common metachromatic dyes are :

Methylene blue

Methyl violent

Thionin

Crystal violent

Toluidine blue

Thionin and toluidine blue dyes are commonly used for quick staining of frozen section using their metachromatic property to stain nucleus and cytoplasm differently.

Tissue components often demonstrated by metachromatic stains :

Amyloid material,

Mast cell granules

Mucin

Cartilage

Direct staining

Application of simple dye to stain the tissue in varying shades of colours.

Indirect staining

It means use of mordant to facilitate a particular staining method or the use of accentuator to improve either the selectivity or the intensity of stain.

Progressive staining

Stain applied to the tissue in strict sequence and for specific times. The stain is not washed out or decolorised because there is no overstaining of tissue constituents. Staining is controlled by frequent observation under microscope

Regressive staining

Tissue is first overstained and then the excess stain is removed from all but the structures to be demonstrated. This process is called differentiation and should always be controlled under microscope.

Decolourization

Partial or complete removal of stain from tissue sections. When the colour is removed selectively (usually with microscopic control) it is called differentiation. In case decolourization is to restrain the selection with some other stain, acid alcohol treatment is the method of choice.

Differentiation

In regressive staining differentiation is the removal of washing out of the excess stain until the colour is retained only in the tissue components to be studies.

Impregnation

It is the deposition of salts of heavy metals on or around cells, tissue constituents etc. It has followed characteristics

1. Structures demonstrated are opaque and black
2. The colouring matter is particulate
3. The deposit is on or around but not in the element so demonstrated.

Histochemical staining

Staining which is used to indicate the chemical composition of the tissue or cellular elements.

Counter stains

A counter stain is the application to the original stain, usually nuclear, of one or more dyes that by contrast will bring out difference between the various cells and tissues. A heavy counterstain is to be avoided lest it mask the nuclear stain. It can be done either by using dilute stain or cutting down the staining time. Some counterstains which are acidic may lighten or remove the nuclear stains.

Mordants

Substance that causes certain staining reactions to take place by forming a link between the tissue and the stain. The link is referred as lake. Without it, dye is not capable of binding to and staining the tissue. e.g. Ammonium and Potassium alum for haematoxylin.

Accentuators

These are substances that causes an increase in the selectively or in the staining power of dye. Thus they lead to more intense staining. e.g. Phenol in Carbol fuchsin, KOH in Mehtylene blue.

Leuco compounds

Conversion of a dye into a colourless compound by the destruction of its chromophore. Prefix leuco is applied to it, e.g. leucofuchsin used in PAS stain.

Dyes used in staining

Dyes are classified in various ways :

- | | | |
|------------------------|------------------------|-------------------------|
| 1. According to source | 2. Affinity to tissues | 3. Chemical composition |
| a. Natural | a. Acidophilic | a. Thiazines |
| b. Synthetic | b. Basophilic | b. Azo-dyes |
| | | c. Rosalins |

Synthetic dyes have greater staining capacity, much greater spectrum of colours.

Natural dyes

These are very few in numbers. They are mainly two in common use.

1. **Haematoxylin** : This is the most popular dye used as a nuclear stain. It is derived from the log tree mainly found in Mexico. It develops staining property after oxidation. It is a weak dye and to make it give sharp stain a mordant is needed.
2. **Carmine** : It is a scarlet dye made from the ground bodies of cochineal beetles.

Synthetic dyes

Most of these are in Aniline base and derived from coal tar. These aniline dyes offer wide range of colour and action. These aniline dyes offer wide range of colour and action. Chemical composition may be basic, acidic, amphoteric (neutral). According to these characters stain different components of tissue.

Basic dyes

These are cationic dyes and stain nuclei, basophilic granules or bacteria.

Acidic dyes

These are anionic dyes and stain mainly cytoplasm, eosinophilic granules.

Theories of staining

Physical theories :

1. Simple solubility e.g. Fat stains are effective because the stain is more soluble in fat than in 70% alcohol.
2. Adsorption: This is a property by which a large body attracts to itself minute particles from a surrounding medium.

Chemical theories

It is generally true that acid dyes stain basic elements (Cytoplasm) and basic dyes stain acidophilic material (nucleus) however this far from being complete truth, Indeed hematoxylin, which is an acid dye, does not stain the cytoplasm, but (in the presence of mordant) is one of the most widely used nuclear stains.

Staining of paraffin section

The most common method of histological study is to prepare thin sections (3-5 micron) from paraffin embedded tissues. These are then suitably stained and mounted in a medium of proper refractive index for study and storage. Commonest mountants used are resinous substances of refractive index close to that of glass. These are soluble in xylol. Hence sections are dehydrated and cleared in xylol and mounted. Mounting in aqueous

mounting media is done directly after staining for sections which cannot be subjected to dehydrating and clearing agents.

The basic steps in staining and mounting paraffin sections are as follows:

1. Deparaffinization
2. Hydration
3. Removal of mercury pigments wherever needed
4. Staining
5. Dehydration and clearing
6. Mounting

1. Deparaffinization

Removal of wax is done with xylol. It is essential to remove the wax completely, otherwise subsequent stages will not be possible. At least 2 to 3 changes in xylol are given for suitable length of time. Sections of this stage should appear clear and transparent. Presence of any patches indicates the presence of wax and sections should be kept longer in the xylol.

2. Hydration

Most of the stains used are aqueous or dilute alcoholic solutions. Hence it is essential to bring the section to water before the stains are applied. The hydration is done with graded alcohols from higher concentration to lower concentration. Alcohol and acetone are miscible with xylol. First change is made to absolute alcohol or acetone followed by 90%, 70% alcohol and finally distilled water.

Sections now should appear opaque. Presence of any clear areas are indicative of the presence of xylol. To remove this xylol, sections should be returned to absolute alcohol and rehydrated.

3. Removal of mercury pigments wherever needed

In case mercury containing fixatives e.g. Zenker, Susa etc are used, mercury pigments are precipitated on the sections. It has to be removed before staining is done. This is brought about by treatment with iodine solutions which changes mercury to an iodine compound. This in turn is converted to tetrathionate by thiosulphate, which is readily soluble in water. The slides are placed in running water to wash out all extraneous chemicals.

4. Staining

Various staining procedures are applied from this hydrated stage. The most common stain applied for histological study is Haematoxylin and Eosin. Various types of haematoxylin formulations are used.

Certain of the stains use strong chemicals e.g. ammonia. Sections tend to float off the slides in such stains. This can be prevented by coating the sections by a thin layers of celloidin. For this sections are returned to absolute alcohol and then dipped in a dilute solution of celloidin and finally hardened in 70% alcohol.

Washing and rinsing of tissue sections is a necessary part of most staining techniques. It eliminates carrying over of one dye solution to the next. Excess dye, mordants, or other reagents might react unfavourably or precipitate when placed in the fluid employed in the next step.

5. Dehydration and clearing

Dehydration is done in graded alcohols or acetones from 70% to absolute alcohol or acetone. Dehydrating alcohol and acetones can remove some of the stains. Time has to be suitably modified to minimize fading of stains.

Since alcohol and acetone are miscible in xylol, it is used for clearing the sections. Any sections from which water has not been completely removed would give a milky appearance after the first xylol. Such sections should be returned to absolute alcohol and the process repeated. Mounting is done after 2nd or 3rd xylol.

6. Cover slipping and mounting

Make quite sure that the sections are quite clear. Do not let the section go dry before mounting

1. Hold the slide between the thumb and the forefinger of one hand and wipe with a clean cloth both ends of the slides. Look for the engraved number to make sure the side the sections is present.
2. Clean carefully around the section and lay on a clean blotting paper with section uppermost along with appropriate coverslip which has already been polished.
3. Place a drop of mountant on the slide over coverslip. Amount of mountant should be just enough. Invert the slide over the coverslip and lower it so that it just adheres to the cover slip quickly turn the

slide over, then lay it on a flat surface to allow the mountant to spread.

Do not press or push the slide at all. It can damage the section.

4. After the mountant has spread to the edge of the coverslip wipe around it for neatness. If proper care has been taken there should be no air bubbles. If many are present, slide should be returned to the xylol to remove the coverslip. It will slip off and remounting is done. No attempt should be made to pull the coverslip. Slight warming of the slide from below will make the small air bubbles to escape from the slide of the coverslip.
5. Coverslip should be in the center of the slide with neatly written label on one slide.

A good knowledge of various mountants and the coverslips is necessary for proper selection of the procedure.

Mountants

Histological sections which need to be examined for any length of time or to be stored, must be mounted under a cover-slip. There are two types of mounting media :

1. Aqueous media - Used for material which is unstained, stained for fat, or metachroamtically stained.
2. Resinous media - For routine staining.

Aqueous media

There are used for mounting sections from distilled water when the stains would be decolorised or removed by alcohol and xylene, as would be the case with most of fat stains (Sudan methods). Some stains, e.g. methyl violet, tend to diffuse into medium after mounting. This can be avoided by using Highman's medium. Aqueous mountants require addition of bacteriostatic agents such as phenol, crystal of thymol or sodium merthiolate to prevent the growth of fungi.

Permanent seal - After mounting the cover slip can be ringed by clear nail polish for storage.

Following are some of the commonly used aqueous mounting media: For formulation see the appendix.

1. Apathy's medium (R.I- 1.52)

A very useful medium for mounting sections for fluorescent microscopy.

2. Farrant's medium (R.I. 1.43)

Recommended for fat stains.

3. Glycerine jelly (R.I. 1.47)

An excellent routine mountant for fat stains.

4. Highman's medium (R.I. 1.52)

Recommended with the metachromatic dyes especially methyl violet.

Resinous mounting media

Natural or synthetic resins dissolved in benzene, toluene or xylene. These are purchased readymade. In case they become too viscous they may have to be diluted with xylene. Following are some of these media.

1. Canada balsam - Natural resin (R.I. - 1.52)

It is used as 60% resin by weight in xylene. H.&E stained slides are fairly well preserved but basic aniline dyes tend to fade and Prussian blue is slowly bleached. Slides take few months to dry.

2. D.P.X. (R.I. 1.52)

Polystyrene resin dissolved in xylene as a 20% solution. It is most commonly used.

3. There are many other synthetic resins sold under various trade names e.g. Coverbond (R.I. 1.53), H.S.R. (Harlew synthetic Resin), Histoclad (R.I. - 1.54), Permount (R.I. 1.54), Pro-Texx (R.I. 1.495).

Criteria of acceptable mounting media

1. Refractive index should be as close as possible to that of glass i.e. 1.5.
2. It should not cause stain to diffuse or fade.
3. It should not crack or appear granular on setting.
4. It should be dry to a nonsticky consistency and harden relatively quickly.
5. It should not shrink back from edge of cover-glass.
6. It should be free flowing and free from air bubbles.

Cover glasses used in histopathology

Care has to be exercised in selecting cover glasses for mounting, these are available in variable sizes and thickness and are supplied usually in 10 gm packings.

Following sizes are commonly available

22 x 22 mm 25 x 50mm

22 x 30 mm Circular

22 x 40 mm

Cover glass should preferably be the No. 1 thickness (0.13 - 0.16 mm), but never more than No. 1 ½ thickness (0.16 - 0.19 mm).

Haematoxylin

Haematoxylin as supplied has no staining properties until it has been ripened by oxidation into haematin. This ripening is achieved by two methods:

1. Exposure of prepared solutions to the air for periods upto 6-8 weeks, preferably in sunlight

or
2. Addition of an oxidizing agent such as sodium iodate, potassium permanganate or mercuric oxide.

In this ripening process Haemtoxylin (C₁₆ H₁₁ & O₆) loses two hydrogen atoms to become Haematin (C₁₆ H₁₂).

Sufficient Haematoxylin should be left unoxidized in solution, so that natural oxidation can continue. It prolongs shelf life of the stain.

Blueing

Alum Haematoxylin stains nuclei and red color, which is converted to blue black color, when the section is washed in weak alkali. Tap water is usually alkaline enough to produce this color change. Following may be used for rapid blueing of the sections.

1. 1% Lithium carbonate.
2. 2% Ammonia (Ammonia Water).
3. Scott's water

Sod. or Pot. Carbonate	2 to 3 gm
Magnesium sulphate	20 gm
Dist. water	1000 ml

There are many formulations for preparing haematoxylin stains. Use of many is a matter of personal preference of whether progressive or regressive staining is being used. In situations where haematoxylin staining is followed by acidic stains, Iron haematoxylin is preferred as it resists decolourisation by these counter stains. Various formulations differ mainly in regards to mordant and the shorter oxidiser used.

Cytoplasmic stains

☐ EOSIN (AFIP)

Eosin 1% stock

Dissolve 1gm of eosin Y water soluble in 20ml of distilled water and 80ml of 95% alcohol.

Eosin working

Stock Eosin - 1 Part

Alcohol 80% - 3 Parts

Add 0.5ml of acetic acid just before use per 100 ml

☐ Eosin Phloxine (AFIP)

Eosin B 1% and distilled

water Eosin Phloxine working

Stock eosin 1% in distilled water - 100ml

Stock Phloxine 1% in distilled water - 10ml

Alcohol 95% 780ml

Acetic acid 4 ml

Working solution to changed weekly

☐ Nuclear fast red (Kernechtrot)

Aluminium sulphate 5 gms

Distilled water 100 ml

Heat and dissolve and cool

nuclear fast red 0.1gm

Dissolved with the aid of heat, cool and filter. Add a crystal of thymol.

Nuclear stains

☐ Hematoxylin Ehrlich's

2% haematoxylin in alcohol 100 ml

3% ammonium or potassium alum in distilled water

100ml Mix the two above and add the following in order

Glycerol 100 ml

Acetic acid 10ml

Keep the bottle loosely plugged

Let it ripen for 1-3 months

☐ Hematoxylin Harris

10% ammonium or potassium alum in distilled water 100 ml

10% alcoholic hematoxylin 10 ml

Bring the alum to boiling point and add the haematoxylin solution carefully till the solution is deep red. Add 0.5 gm of red oxide of mercury, solution becomes deep purple. Promptly remove the flame and plunge into ice cold water. This is the most important part. Leave over night at room temperature and filter. Add 2 or 4 ml of acetic acid before use per 100 ml in the stain.

Note: In place of red oxide of mercury 0.177 gm. of potassium permanganate can be used but should added after cooling the solution and never while boiling.

□ Hematoxylin phosphotungstic acid Mallory's

Haematoxylin 1.0gm

Phosphotungstic acid 20gm

Distilled water 1000 ml

Dissolve haematoxylin and phosphotungstic acid separately in distilled water with the aid of heat, when cool, combine the solution and make upto 1 litre with distilled water. Let it stand for 5-6 weeks before use. Staining time - 12-24 hours

Note : Quick ripening may be done by adding 0.177 gm of potassium permanganate. However the results are not so good.

☐ Weigert's iron Hematoxylin

A. Haematoxylin 1gm

Alcohol 100 ml

Let it ripen for a week

B. 30% solution of ferric chloride

4ml Distilled water 100 ml

Hydrochloric acid (conc.) 1 ml

Immediately before use mix equal parts of A&B add B to A and not vice versa.

Staining time 20-30 minutes

☐ Mayer's Hematoxylin

Hematoxylin 1gm

Distilled water 1000ml

Heat distilled water to 55 to 60°C and add hematoxylin rotate till dissolved.

Ammonium or potassium alum 50 gms

Sodium iodate 0.20gm (to be weighed exactly)

Add the above in order given

Citric acid 1gm

Chloral hydrate 50.0 gm

Above must added in order given. Allow to stand overnight before use. Solution is stable for 6-8 weeks. Staining time 6-8 minutes to increased after a month.

Some basic rules for staining

1. Keep stains and solutions covered when not in use.
2. After the slides are removed from oven these should be cooled before being put in xylene.
3. Filter stains before use.
4. Once the slides have been put in the xylene to remove paraffin they should not be allowed to dry out. Particular care must be taken not to let the sections dry at the time of mounting as the xylene easily evaporates and if the section dried before mounting preparation would become useless.
5. Care should be taken that level of any solution used during staining is such as to cover the slides.
6. Drain the slides well and blot the bottom on filter paper before putting into the next solution. This is particularly necessary in transferring from 95% to absolute alcohol and absolute alcohol in xylol.
7. Xylol used to remove paraffin should not get mixed up with the clearing xylol. It also should be frequently changed as it tends to get saturated.
8. If for blueing an alkali e.g ammonia has been used, it should be well washed out. Failure to do that will lead to disagreeably hazy blue colour of nuclei.

Haematoxylin and Eosin staining

Procedure

- ◆ Deparaffinize in hot air oven.
- ◆ Hydrate the section.
 - i) 3 dips in xylene (2 Min. each)
 - ii) 3 dips in acetone / alcohol (2 Min. each)
 - iii) In running tap water for 5 Minutes.
- ◆ Mayer's haematoxylin for 15 minutes.
- ◆ Wash in running tap water for 20 minutes
- ◆ Counter stain with eosin for 2 minutes
- ◆ Dehydrate the section in 95% and absolute alcohol/ acetone 2 changes (2minutes each).
- ◆ Clear in xylene 3 changes (2 minutes each)
- ◆ Mount in DPX

Results

Nucleus - blue

Cytoplasm and background - pink

Causes of poor quality of staining

1. Poor or inadequate fixation of tissue.
2. Over or under-ripened Haematoxylin.
3. Overused or worked out Haematoxylin.

4. Over or under differentiation of haematoxylin
5. Insufficient blueing following differentiation.
6. Failure to wash blueing agent out of section before counter staining with eosin (especially when ammonia is used).
7. Insufficient differentiation of eosin during washing or dehydration.
8. Insufficient dehydration and clearing of sections.
9. Contamination of stains.

PHOENIX PARAMEDICAL COLLEGE PULWAMA KASHMIR

CHAPTER 7 : SPECIAL STAINING

VAN GIESON METHOD

Mode of teaching - Practical demonstration.

Aim : Staining of the connective tissue

Principle : In the routine staining method collagen, elastic fibres and smooth muscle appear pink or reddish in colour.

In the Van Gieson stain, collagen and most reticulin stain selectively with acid aniline dyes (acid fuchsin). Picric acid acts as counter stain for muscle and cytoplasm and form complex with the dyes. This complex has special affinity for collagen.

Reagents

1. Solution A
 - (a) Haematoxylin 1.0 gm
 - (b) Alcohol 95% 100 ml
2. Solution B
 - (a) 29% (w/v) ferric chloride 4 ml
 - (b) Conc. Hydrochloric acid 1.0 ml
 - (c) Distilled water 95.0 ml
3. Weight's iron haematoxylin solution :mix equal quantities of solution A and solution B. Colour of this reagent should appear violet black.
4. Van Gieson's solution
 - (a) Saturated aqueous picric acid – 10 ml
 - (b) 1% (m/v) acid fuchsin – 1.5ml

It should be freshly prepared

Procedure

- (1) Deparaffinize with xylene
- (2) Hydration take sections to water
- (3) Stain with Weigert's haematoxylin for 20-40 minutes
- (4) Wash in distilled water
- (5) Van Gieson stain 1-3 min
- (6) Rinse well in distilled water
- (7) Dehydrate in absolute alcohol (2 changes)
- (8) Clear in xylene (2 changes)
- (9) Mount in DPX

Results

- | | | |
|----|---------------------------------|---------------|
| 1. | Collagen | Red |
| 2. | Muscle and Cornified epithelium | Yellow |
| | (B) Nuclei | Blue to Black |

Clinical significance

Several pathological changes are associated with cellular changes in connective tissues. Histological diagnosis of collagen diseases is based on the study of the section of various connective tissues.

GOMORI'S METHOD FOR RETICULUM

Mode of teaching - Practical demonstration.

Aim – Demonstration of reticulum fibres by silver nitrate method.

Principle : In the connective tissue, reticulin appears as a fibrillary extracellular framework. Reticular fibres have low natural affinity for silver salts and require pretreatment with heavy metal solutions like ferric ammonium sulphate to enhance the selectivity of impregnation. Silver in alkaline solution is in a state readily able to precipitate as metallic silver. Upon treatment with a reducing agent, silver taken up by the tissue in unreduced form is, converted to metallic silver which is deposited at the sensitised site.

Reagents

1. Ammonical silver solution

To 10 ml of 10% silver nitrate solution add 2.5 ml of 10% aqueous solution of potassium hydroxide, add 28% ammonium hydroxide drop by drop while shaking the container continuously until the precipitate is completely dissolved. Add again 4 drops of silver nitrate solution for every 10 ml of silver nitrate used. Make the solution with distilled water to twice its volume use acid clean glassware

2. 0.5% potassium permanganate –

Potassium permanganate –0.5 gm

Distilled water 100 ml

3. 2% potassium metabisulphite

Potassium metabisulphate 2.0 gm

Distilled water 100 ml

4. 2% ferric ammonium sulfate solution

Ferric ammonium sulphate 2 gm

Distilled water 100 ml

5. 20% formalin solution

Formaldehyde 20 ml

Distilled water 80 ml

6. 0.2% gold chloride solution

Gold chloride solution 1% - 10 ml

Distilled water - 40 ml

7. 2% sodium thiosulphate solution

sodium thiosulphate 2 gm

Distilled water 100 ml

Procedure

1. Deparaffinize and hydrate to distilled water
2. Oxidize in potassium permagnate solution for 1 minute
3. Rinse well in tap water – 2 min
4. Differentiate with potassium metabisulphite solution for 1 minute.
5. Wash in tap water for 2 min
6. Sensitize in Ferric ammonium sulphate solution for 1 min.
7. Wash in tap water for 2 minutes follow with two changes of distilled water 30 seconds each.

8. Impregnate in the silver solution for 1 minute
9. Rinse in distilled water for 20 seconds
10. Reduce in formalin solution for 3 minutes
11. Wash in tap water for 3 minutes
12. Tone in gold chloride solution for 10 minutes
13. Rinse in distilled water
14. Reduce in potassium metabisulfite solution for 1 minute
15. Fix in sodium thiosulfate solution for 1 minute.
16. Wash in tap water for 2 minutes.
17. Dehydrate in 95% alcohol, absolute alcohol and clear in xylene 2 changes
18. Mount in DPX.

Results

Reticulin fibers – black

Background – grey

Clinical significance

This type of staining is used for tumors of uncertain origin. The pattern of deposition of reticulin in a tumor is characteristic to identify the origin of tumor.

Mild degree of fibrosis in organs can also be recognized by reticulin stain especially in liver to assess cirrhosis.

McMANUS FOR GLYCOGEN (PAS)

Mode of teaching - Practical demonstration.

Aim – Staining and identification of the various types of carbohydrates (polysaccharides & mucopolysaccharides).

Principle : Tissue structures like liver & heart, striated muscles are studied by Periodic acid Schiff stain. Periodic acid reacts with aldehyde group of the carbohydrates and afterwards reaction with the schiff's reagent produces a red or purple red colour.

Reagents

1. 0.5% w/v periodic acid solution
2. Schiff's reagent
 - (a) Dissolve 1.0 gm of basic fuchsin in 100 ml of boiling distilled water cool to about 60 degrees and filter.
 - (b) Add 20 ml of 0.1 N hydrochloric acid, cool further and add 1.0 gm of sodium metabisulphite and mix well.
 - (c) Keep in the dark for 24-48 hours. When the solution becomes straw coloured, add 300 mg of activated charcoal, shake vigorously, filter and store.
3. 1 N Hydrochloric acid
4. 0.1 gm of light green in 100 ml of 0.1% (v/v) acetic acid.
5. Harris haematoxylin stain

Procedure

1. Deparaffinize and hydrate to distilled water.
2. Oxidize in periodic acid solution for 5 minutes
3. Rinse in distilled water
4. Schiff's reagent solution for 15 minutes.
5. Wash in running water for 10 minutes for pink colour to develop.
6. Harris haematoxylin for 6 minutes or light green counter stain for a few seconds.
7. Wash in running water.
8. Differentiate in 1% acid alcohol solution 3-10 quick dips.
9. Wash in running water.
10. Dip in ammonia water to blue the sections
11. Wash in running water for 10 minutes
12. Dehydrate in 95% alcohol, absolute alcohol, clear in xylene two changes each.
13. Mount in DPX.

Results

With hematoxylin counterstain

1. Nuclei – blue
2. Glycogen, mucin, hyaluronic acid, reticulin, colloid droplets, amyloid infiltration, thrombi. – purple red
3. Fungi – Red
4. Background – pale green (with light green counter staining).

Test for schiff reagent solution

Pour a few drops of schiff reagent solution into 10 ml of formaldehyde (37-40%) in a watch glass. If the solution turns reddish purple rapidly it is good. If the reaction is delayed and the resulting colour deep blue purple the solution is breaking down.

PHOENIX PARAMEDICAL COLLEGE PULWAMA KASHMIR

MAYER'S MUCICARMINE METHOD

Mode of teaching - Practical demonstration.

Aim : To demonstrate mucin in a tumor or epithelium

Principle :

The rationale for specificity of mucicarmine for mucin is not fully understood by the probable mechanism is that the aluminium salts in the solution form a chelate compound with carmine, thus producing a net positive charge on the molecule and consequent binding to the tissue polyanions.

The compound has a large molecular size and allows that dye complex to penetrate and bind to acidic substrates of low density like mucins other acidic substances like nucleic acid are of high density hence exclude the mucicarmine.

Reagents

(1) Weigert's Iron haematoxylin solution

(a) Solution A

Hematoxylin crystals 1.0 gm

Alcohol 95% 100 ml

(b) Solutions B

Ferric chloride 29% aqueous 4 ml

Hydrochloric acid conc. 1 ml

Distilled water 95 ML

Working solution – Add equal parts of solution A and solution B

(2) Mucicarmine solution

Carmine	1 gm
Aluminium chloride anhydrous	0.5 gm
Distilled water	2 ml

Mix stain in small evaporating dish. Heat on electric hot plate for 2 minutes. Liquid becomes black and syrupy. Dilute with 100 ml of 50% alcohol and let it stand for 24 hours filter.

Dilute 1 part of mucicarmine solution with 4 parts of tap water for use.

(3) 0.25% Metanil yellow solution

Melanil Yellow	-	0.25 gm
Distilled water	-	100 ml
Glacial acetic acid	-	0.25 ml

Procedure

1. Deparaffinize and hydrate to distilled water.
2. Working solution of Weigert's Haematoxylin for 7 minutes.
3. Wash in running water for 10 minutes
4. Diluted mucicarmine solution for 60 minutes
5. Rinse quickly in distilled water.
6. Metanil yellow solution for 1 minute.
7. Rinse quickly in distilled water

8. Dehydrate in 95% alcohol, absolute alcohol and clear in xylene 2 changes each.
9. Mount with DPX.

Results

Mucin – Deep rose to red.

Capsule of cryptococcus - deep rose to red.

Nuclei - Black

Other tissue elements - yellow

Clinical significance – Certain tumors are mucin producing demonstration of mucin in such tumors confirms their origin especially in poorly differentiated or moderately differentiated tumors.

FITE's method for acid fast organisms

Aim : to demonstrate weakly acid fast bacilli like mycobacterium Lepre and Nocardia.

Principle: The mycobacteria are the bacteria which are relatively resistant to staining because of the lipid capsule which surrounds them, when stained by a strong stain (eg carbol fuchsin) they resist decolourization by acid. In this method a red dye carbol fuchsin is forced into the bacteria and other structures with heat and is then removed from other structures with acid or alcohol ; tubercle bacillus because of lipid capsule however resists decolourization.

Reagents

1. Xylene – peanut oil solution

Peanut oil - 1 part

Xylene - 2 parts

2. Ziehl Neelsen Carbol Fuchsin solution

-	basic fuchsin	1 gm
-	Phenol	5 gm
	Distilled water	100 ml
	Absolute alcohol	10 ml

Basic fuchsin is dissolved in alcohol and added to phenol in distilled water. Filter before use

3. 1% (v/v) sulphuric acid solution
4. Methylene blue solution 0.25% methylene blue in 1% glacial acetic acid.

Procedure

1. Deparaffinize through 2 changes of xylene peanut oil solution for 12 minutes each.
2. Drain wipe off excess oil & blot to opacity.
3. Carbol fuchsin solution for 30 minute
4. Wash in tap water for 3 minutes & blot dry.
5. Differentiate slides with sulfuric acid solution till sections are faint pink for 1-2 minutes.
6. Wash in running water for 3 minutes

7. Counterstain lightly with working methylene blue solution (few seconds).
8. Rinse off excess methylene blue in tap water.
9. Blot and let it stand for few minutes to air dry thoroughly.
10. Dip slides in xylene before mounting.
11. Mount with DPX

Results

M. Leprae - red

Nocardia filaments - blue grey

Gomori's method for iron

Aim : Staining of section for haemosiderin (a tissue pigment)

Principle: Haemosiderin is a brown granular pigment occurring at the site of previous haemorrhage. It is a product of the breakdown of haemoglobin. It reacts with potassium ferrocyanide in acid medium and yields a Prussian blue colour.

Reagents

1. Solution A - 20% hydrochloric acid solution (stock)
 - Hydrochloric acid (conc.) 20ml
 - Distilled water 80ml
 - Distilled water 80ml
2. Solution B - 10% potassium ferrocyanide solution (stock)
 - Potassium ferrocyanide 10 gm
 - Distilled water 100ml

3. Acidified potassium ferrocyanide solution. Prepare fresh by mixing equal part of solution A and solution B and leave for 20 minutes
4. Nuclear fast red stain. Dissolve 5.0 gm of aluminium sulphate in hot distilled water and add 0.1 gm of nuclear fast red mix well and filter. Add a crystal of thymol as a preservative.

Procedure

1. Deparaffinize and hydrate to distilled water
2. Put the slides in acidified potassium ferrocyanide solution for 30 minutes
3. Rinse in distilled water
4. Counterstain in nuclear fast red solution for 5 minutes.
5. Rinse in distilled water
6. Dehydrate in 95% alcohol, absolute alcohol, and clear in xylene 2 changes each
7. Mount with DPX

Results - Iron pigments - bright blue

Nuclei - Red

Cytoplasm - Light pink.

VON KOSSA'S METHOD FOR CALCIUM

Mode of teaching - Practical demonstration.

Aim : Staining of the sections for calcium **Principle** - The calcium salts in the form of phosphates, carbonates or oxalates occur as components of oxalates occur as components of laminated concentration in various organs such as the kidneys, urinary bladder, lymph nodes. Von Kossa's technique in a metal substituted for calcium by metallic salt formation with the anion of the calcium salt.

Reagent :

1. 5% W/v silver nitrate solution (stored in amber coloured bottle)
2. 5% W/v sodium thiosulphate solution
3. Nuclear fast red stain. Dissolve 0.1 gm nuclear fast red no 100 ml of 5% solution of aluminium sulphate with the aid of heat. Cool filter add grain of thymol as a preservative.

Procedure (Use control slides and chemically clean glassware)

1. Deparaffinize and hydrate to distilled water
2. Silver nitrate solution expose to bright sunlight or under the light of 100 watt bulb for 60 minutes
3. Rinse in Distilled water
4. 5% sodium thiosulfate solution for 2 minutes
5. Rinse well in distilled water
6. Counter stain with nuclear fast red solution for 5 minutes
7. Rinse in distilled water

8. Dehydrate in 95% alcohol, absolute alcohol and clear in xylene 2 changes each
9. Mount with DPX

Results

Calcium salt	-	Black
Nuclei	-	Red
Cytoplasm	-	Light pink

HALL'S METHOD FOR BILIRUBIN

Mode of teaching - Practical demonstration.

Aim : To stain the bilirubin or bile pigment in tissue section **Principle** -

Bilirubin is oxidized to biliverdin and stains olive green to emerald green depending on the concentration of bilirubin in solution.

Reagents

1. Fouchet's Reagent

Trichloroacetic acid - 25.0gm

Distilled water 100ml

Mix and add 10 % ferric chloride

2. 10% Ferric chloride solution

Ferric chloride - 10gm

Distilled water - 100ml

3. Van Gieson's solution

(a) Saturated aqueous picric acid 10ml

(b) 1% w/v acid fuchsin 1.5ml

Procedure

1. Deparaffinize and hydrate to distilled water
2. Fouchet's reagent for 5 minutes
3. Wash in running water, then in distilled water
4. Van Gieson's solution for 5 minutes
5. Dehydrate in 95% alcohol, absolute alcohol and clear in xylene 2 changes each
6. Mount with DPX

Results

Biliverdin green

Collagen red

Muscle Yellow

Removal of pigments – Melanin

- A. Deparaffinize and hydrate and rinse in distilled water
0.25% potassium permanganate – 30-60 min. Wash well in water
5% oxalic acid till clear 2-5 min.

Wash in tap water followed by rinse in distilled water

Or

- B. Deparaffinize and hydrate to distilled water

Keep in 10 volumes of hydrogen peroxide – 24 hours Wash in distilled water

Or

- C. 1% hydrochloric acid overnight wash well in water followed by wash in distilled water.

Removal of pigments formalin

1. Deparaffinize and hydrate to distilled water
2. Let it stand in saturated alcoholic picric acid – 3 hours
3. Wash in running water till the yellow colour is removed.

PHOENIX PARAMEDICAL COLLEGE PULWAMA KASHMIR

References

1. Bancroft, J.D. and Stevens, A.: theory and practice of histological techniques ed.3, Churchill livingstone inc. 1990. Edinburgh. London, Melbourne and New York.
2. Lillie, R.D.: Histopathologic technique and practice histochemistry ed. 3, New York, 1965 McGraw Hill Book co.
3. Manual of histologic and special staining techniques ed. 2, New York, 1960, The Blakiston Division McGraw Hill Book Co.
4. Pearse A.G.E.: Histochemistry, ed. 2, Boston 1960, Little Brown and Co.
5. H.J. Conn's Biological Stains (1969) Lillie, R.D. 8th edn, Baltimore; Williams and Wilkins